



CASE 54

Cirurgião: **DANIEL NASTRI DE LUCA**

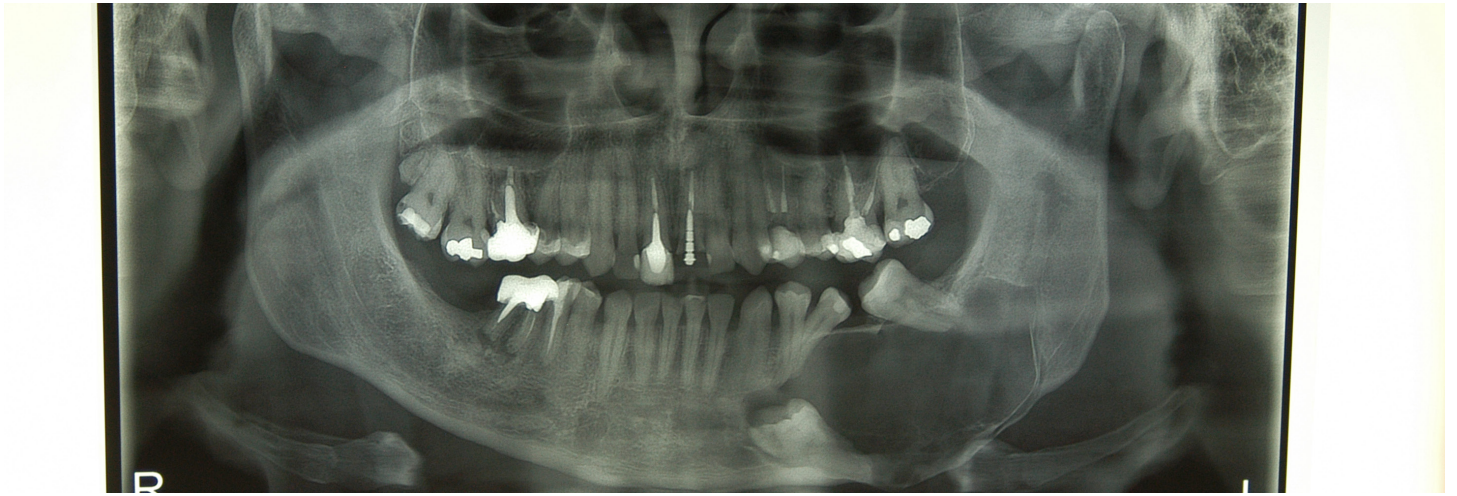
Diagnóstico: Cisto Odontogênico Ortoqueratinizado [COO] em Mandíbula

Histórico: Cisto em região mandibular E - achado radiográfico. HD: Cisto odontogênico ortoqueratinizado.

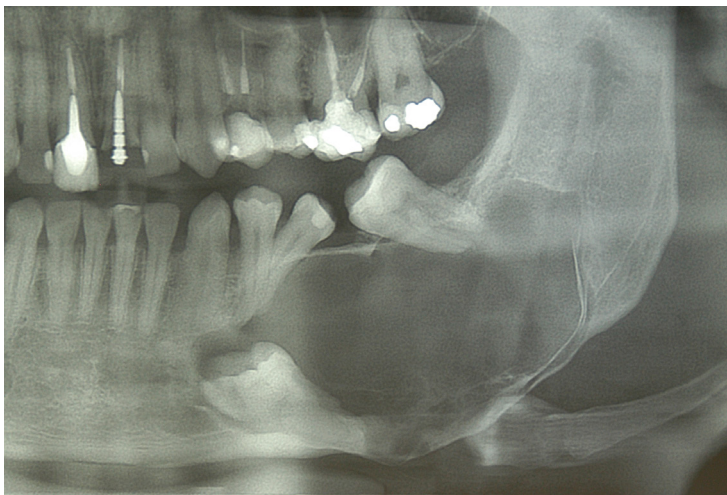
Exérese de Cisto Ortoqueratinizado em corpo mandibular E

Paciente: W.A.S, 31 anos, sexo masculino

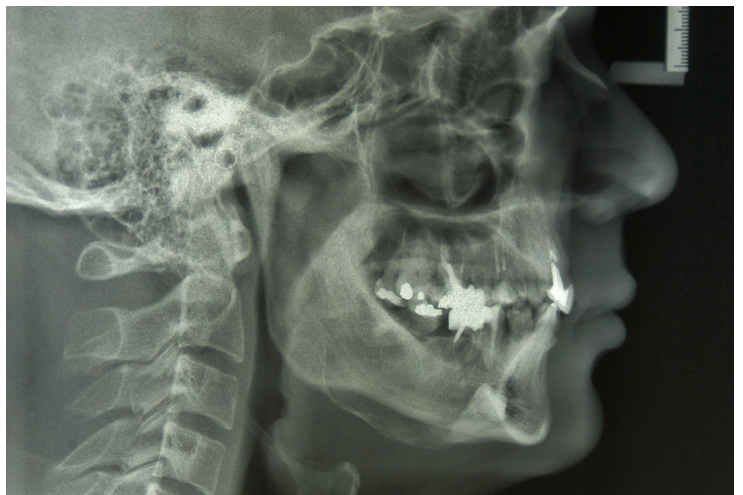Ao EC, aumento de volume em região lingual do corpo mandibular E. Na radiografia panorâmica, apresenta lesão expansiva em corpo mandibular E e dente retido dentro da lesão. Na TC, lesão osteolítica em corpo mandibular E, com pequena expansão na vestibular e grande na lingual. NAI deslocado para basal. Feita exérese total da lesão sob anestesia geral. Incisão muscular com laser de diodo e descontaminação da loja cirúrgica com laser de alta potência. Colocação de placa de reconstrução + enxerto de hidroxiapatita 10g [Bionnovation] com I-PRF [steak bone] + membranas de L-PRF e colágeno.



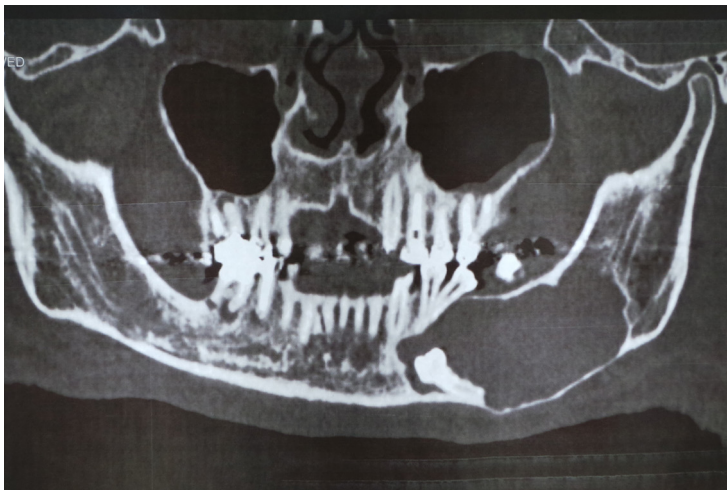
Radiografia Inicial [14 SET 2016]



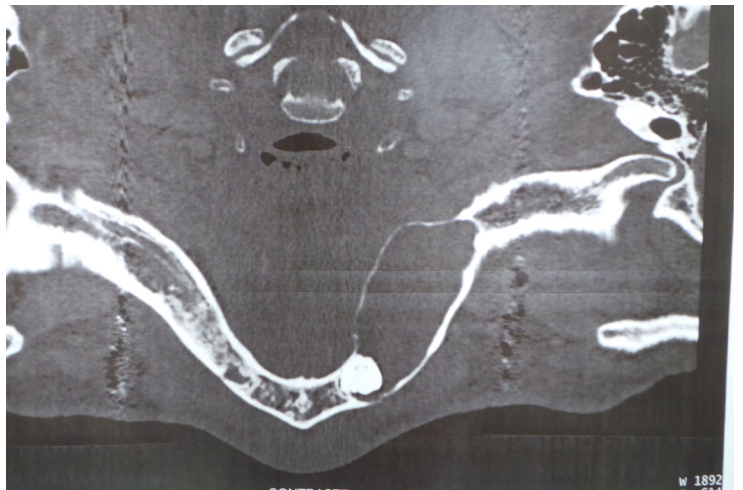
Radiografia Inicial [14 SET 2016]



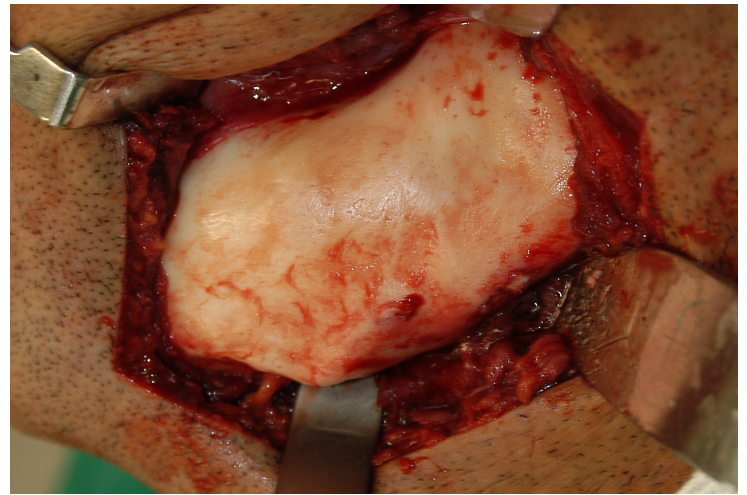
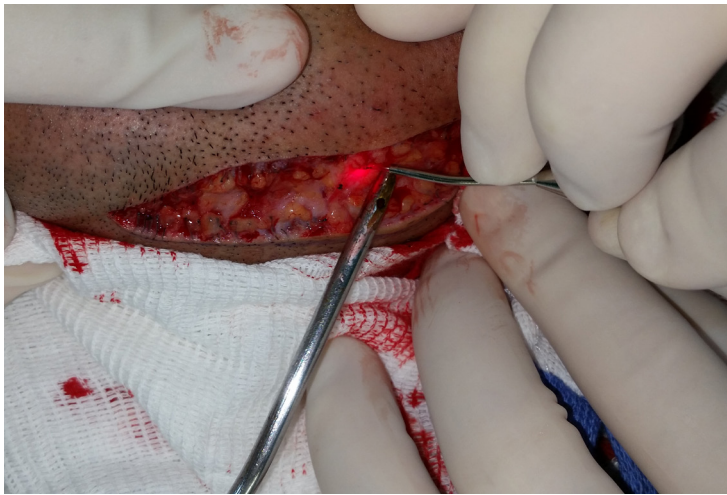
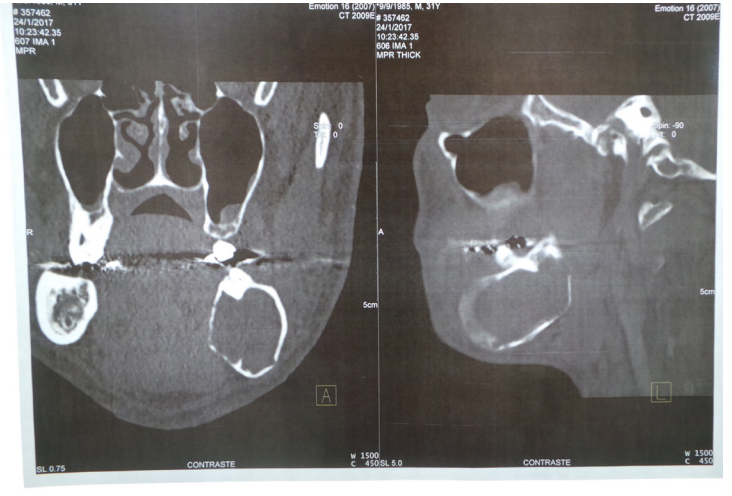
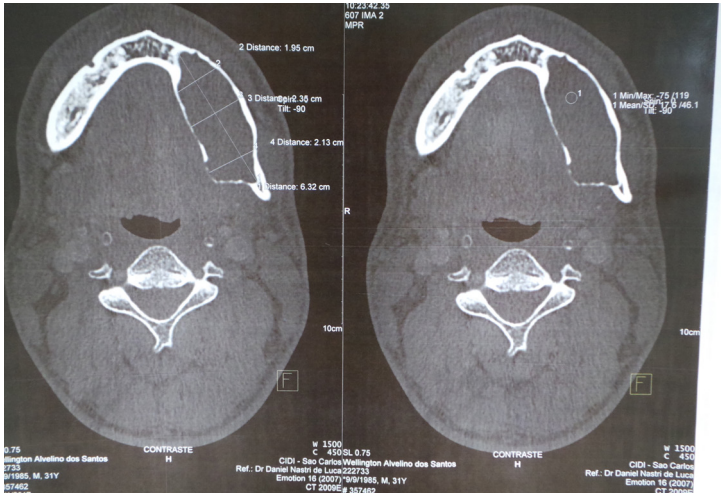
Radiografia Inicial [14 SET 2016]



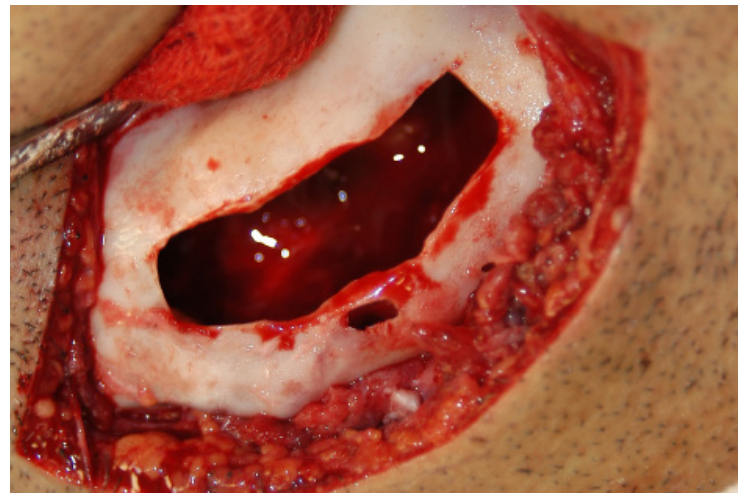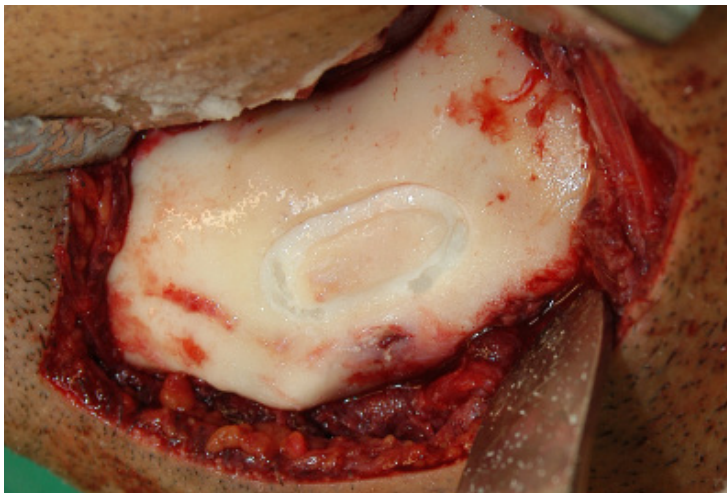Radiografia pré-cirúrgica [24 JAN 2017]

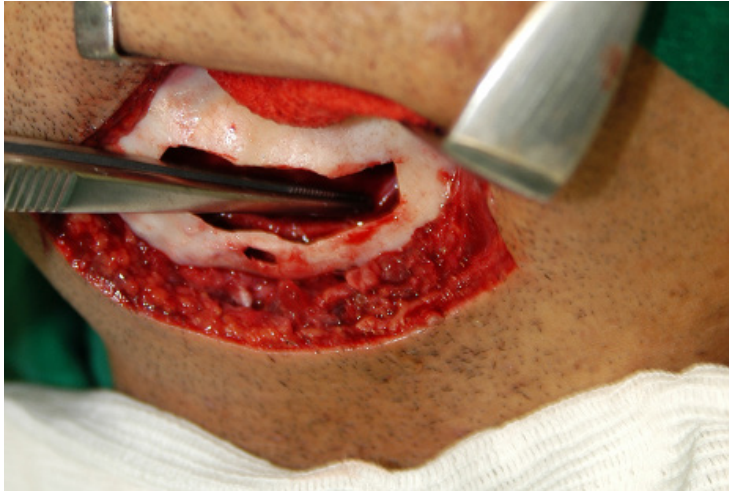


W 1892
C 614

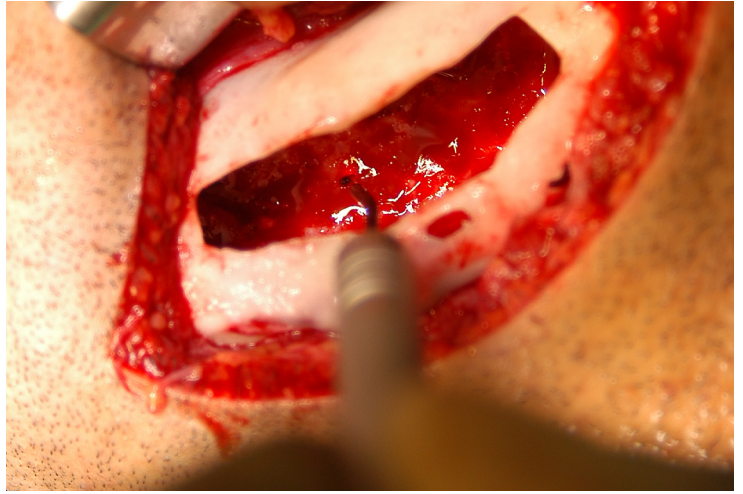


Dissecção com laser de diodo cirúrgico

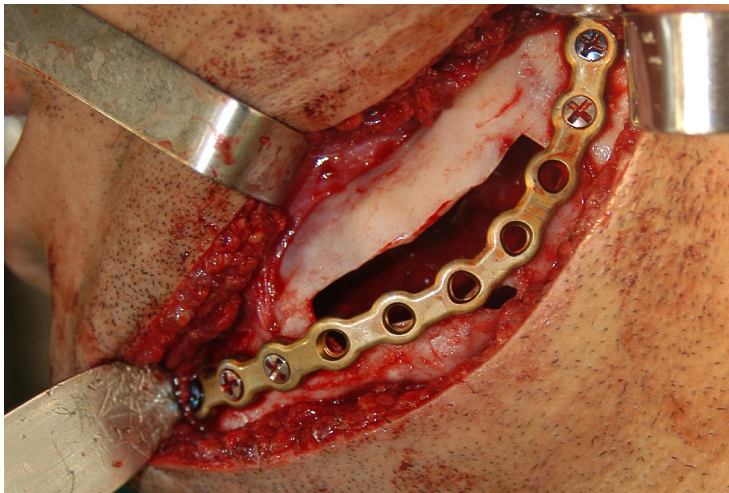




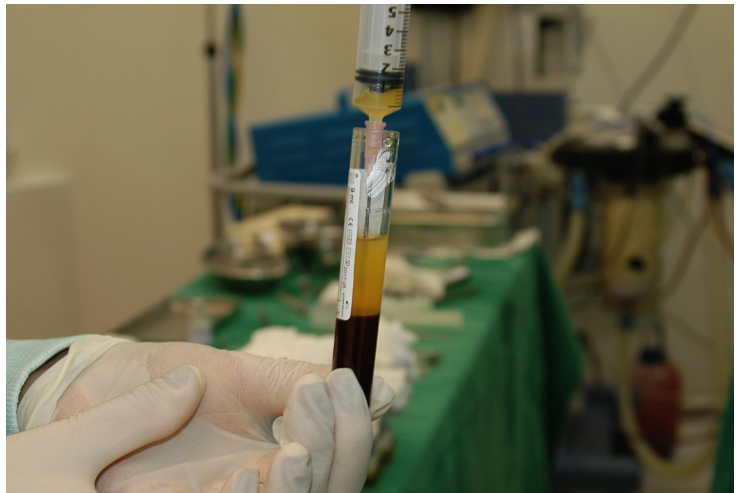NAI exposto após exérese cística



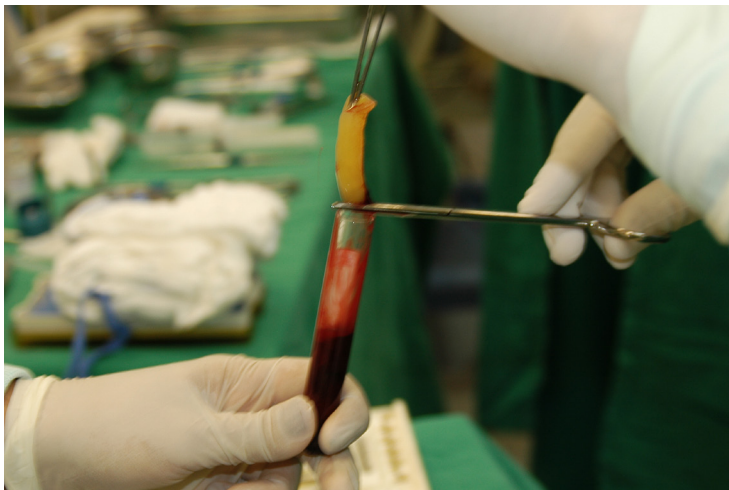**Vaporização tecidual e descontaminação com laser
[Marca DMC]**



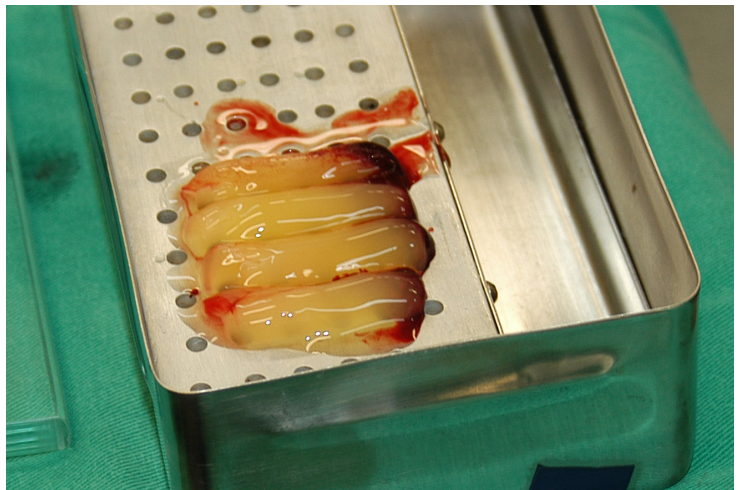
Colocação de placa e parafuso de fixação



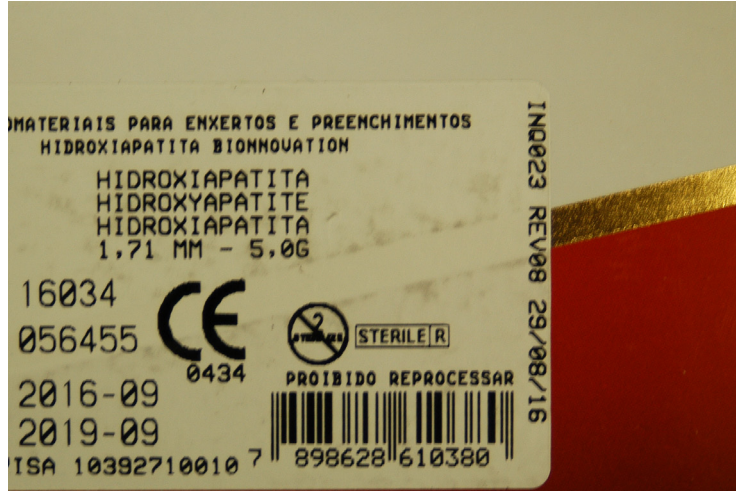

Coleta do L-PRF no tubo



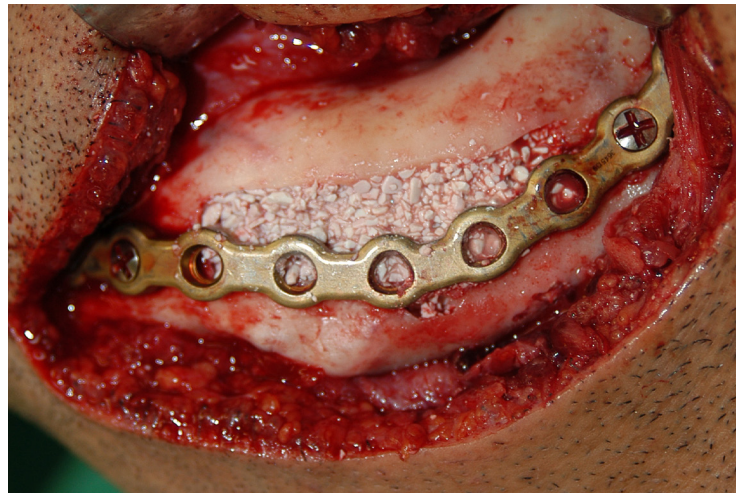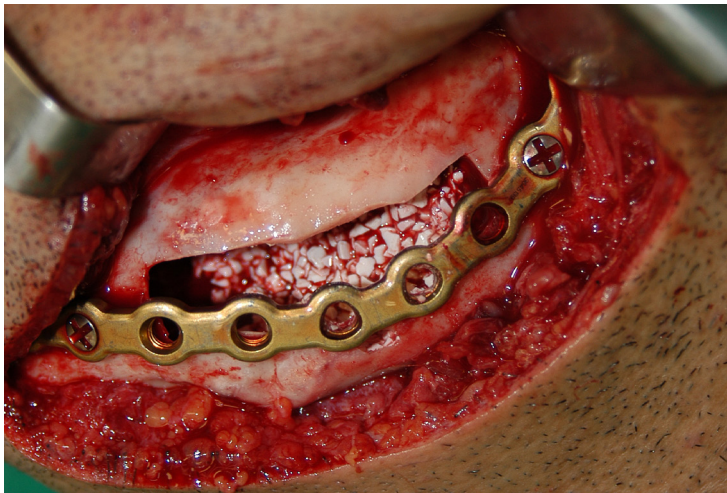Coleta do coágulo de L-PRF



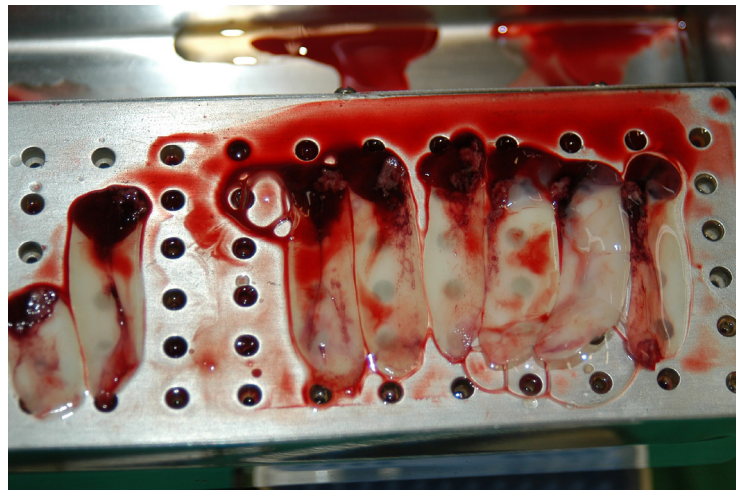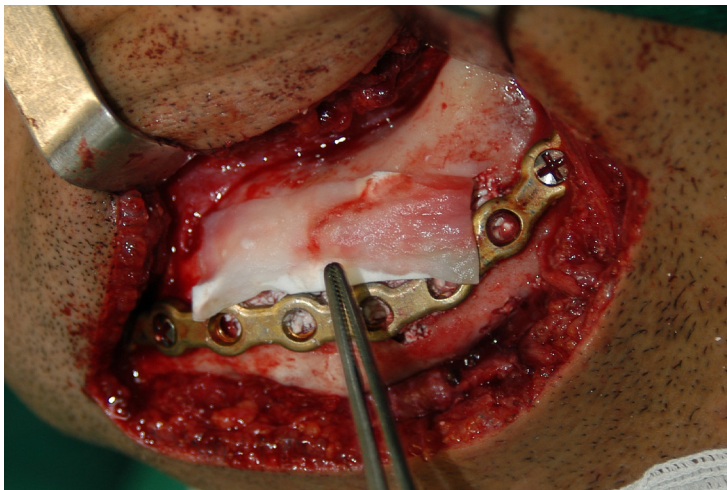
Coágulo de L-PRF



Preparação do Sticky Bone com Hidroxiapatita [Cod 16034 Lote 056455]

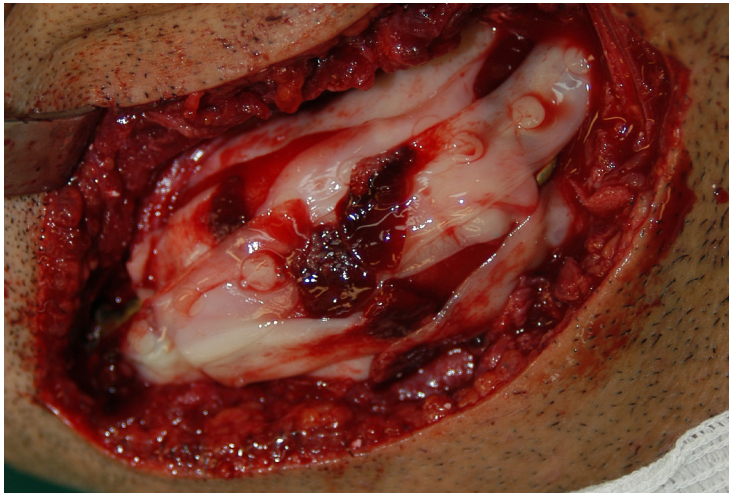


Cavidade preenchida com Hidroxiapatita

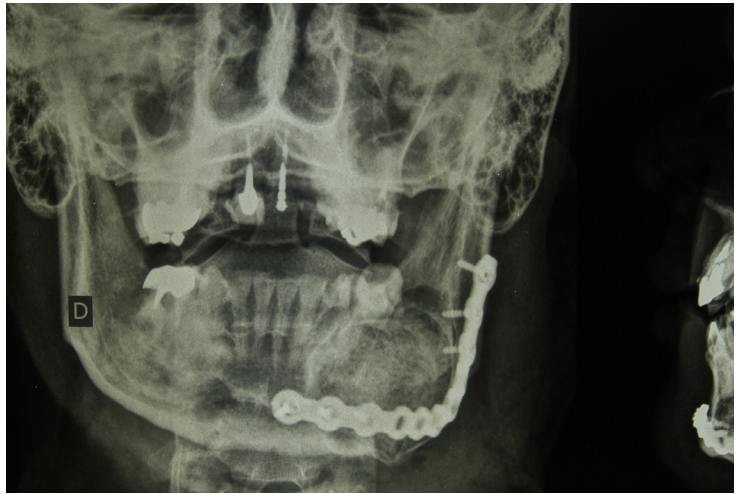


Membranas de colágenos posicionadas

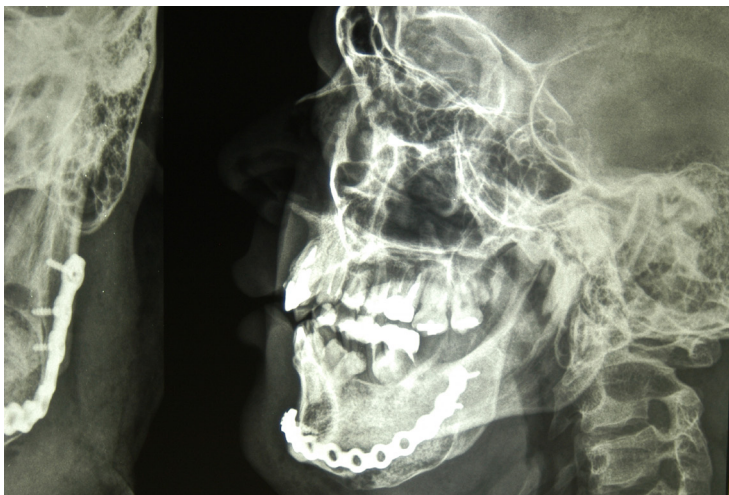Membranas de L-PRF



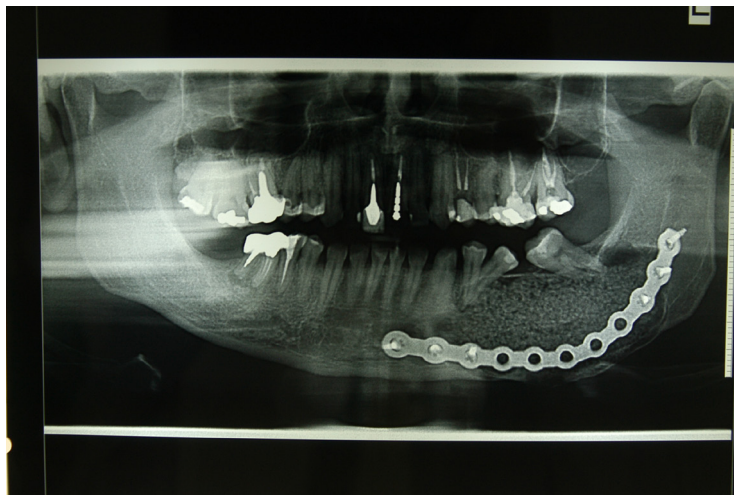
Colocação da **membrana L-PRF** sobre membranas de colágenos



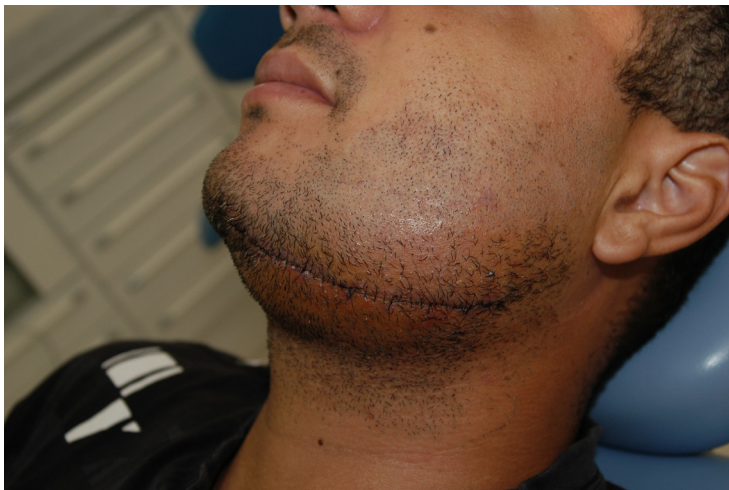PO Imediato [13 MAR 2017]



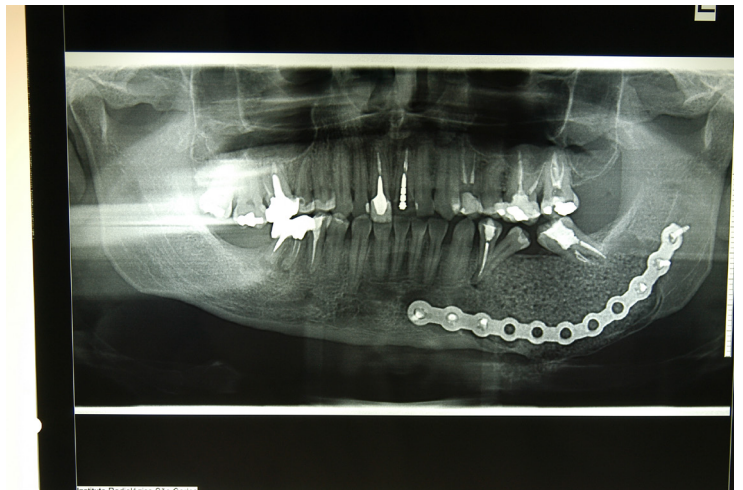
PO Imediato [13 MAR 2017]



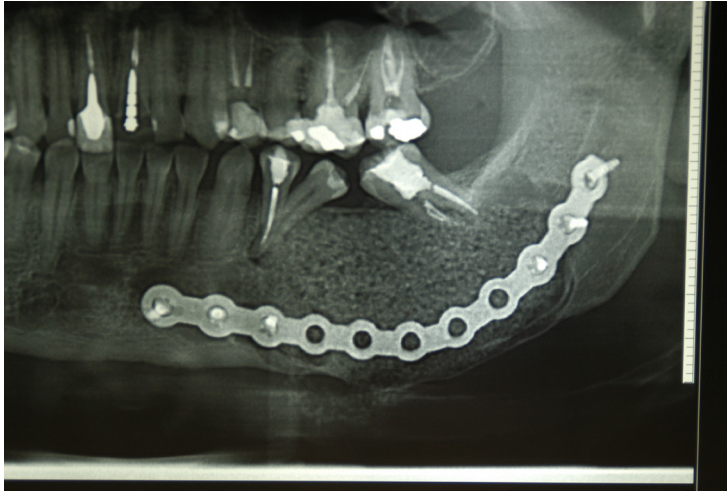
Follow Up 7 dias [20 MAR 2017]



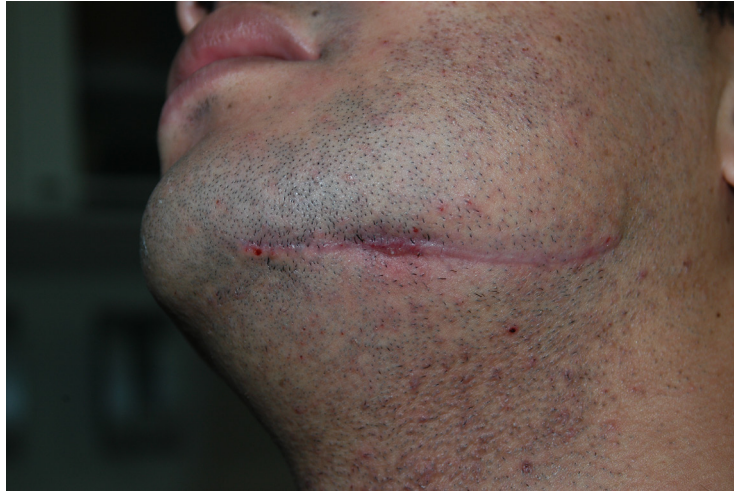Follow Up 7 dias [10 ABR 2017]



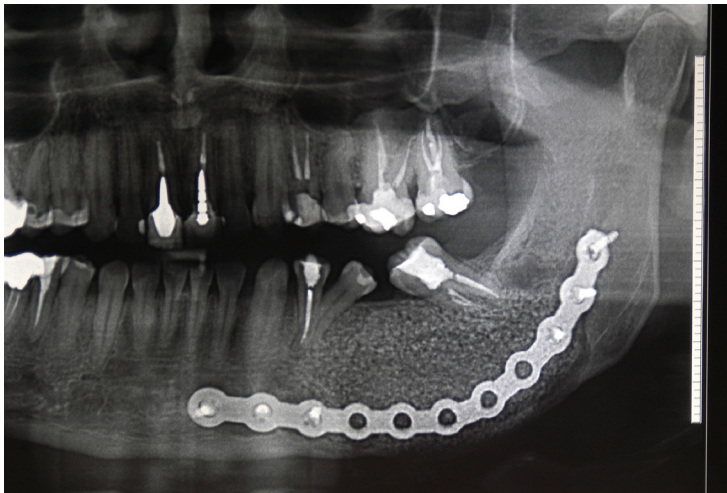
Follow Up 24 dias [06 ABR 2017]



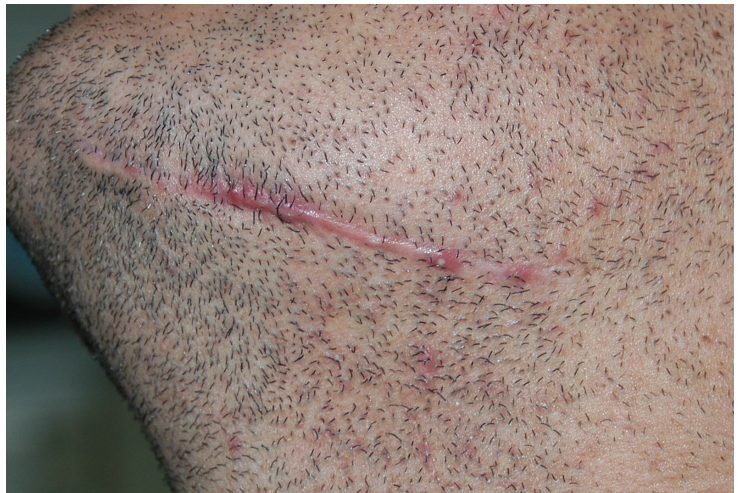Follow Up **24 dias** [06 ABR 2017]



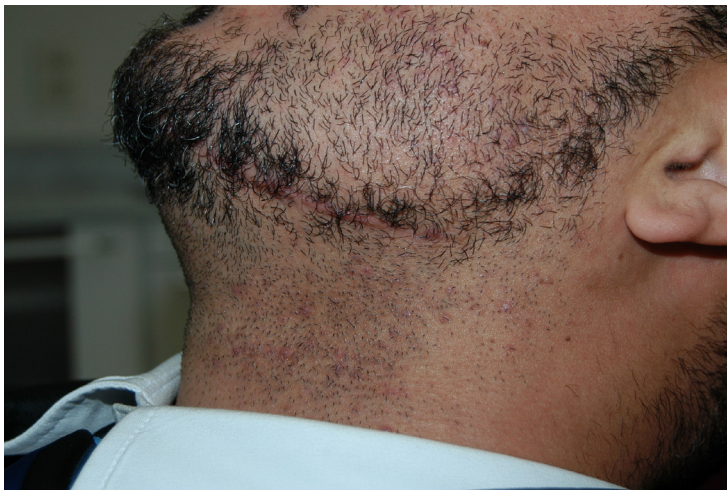Follow Up **57 dias** [09 MAI 2017]



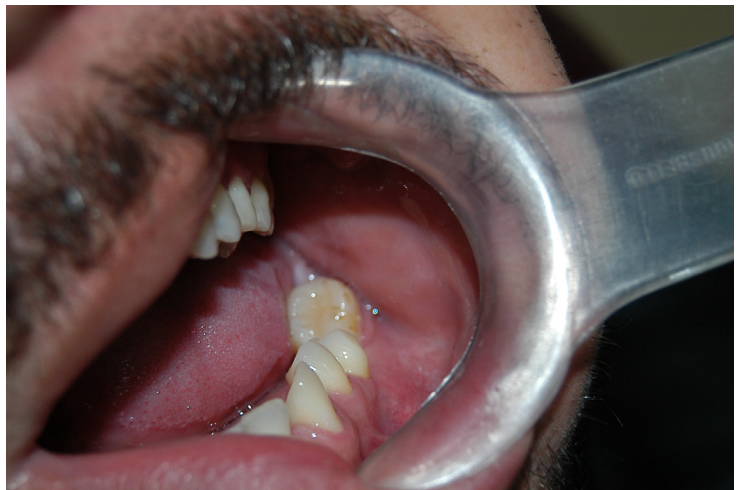Follow Up **120 dias** [11 JUL 2017]



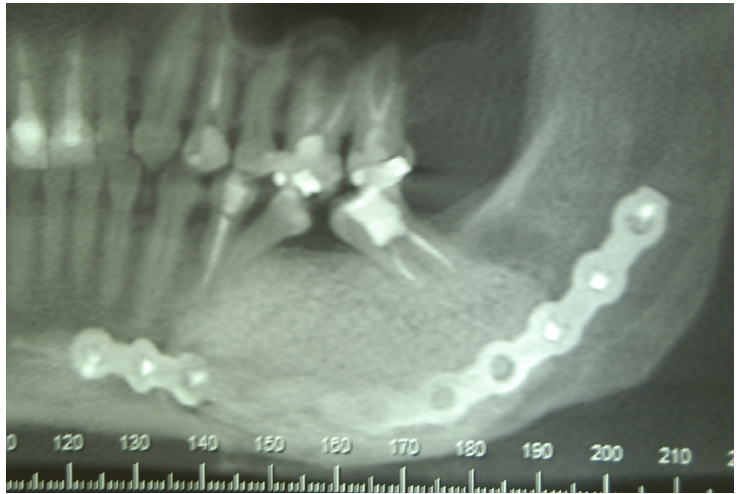
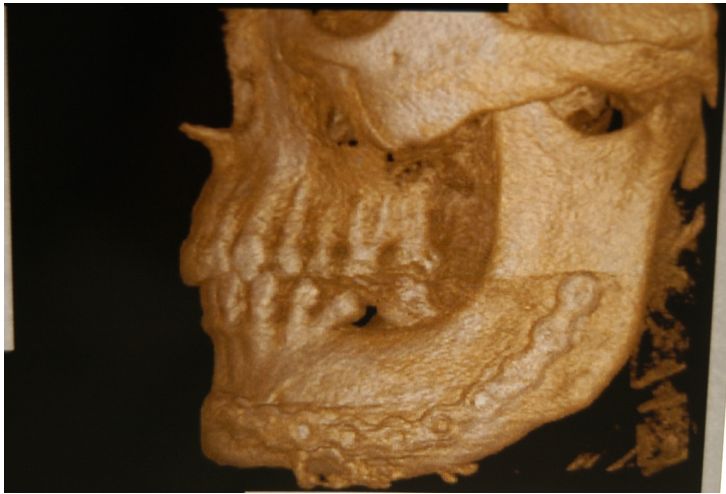
Follow Up **≈ 7 meses** [03 OUT 2017]



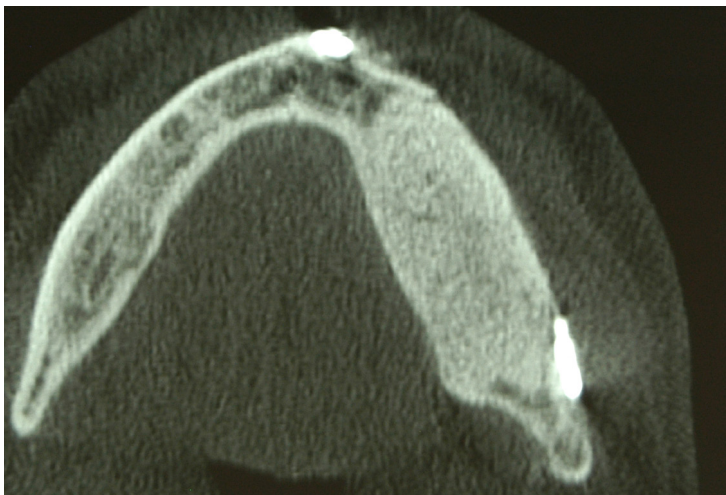
Follow Up **≈ 15 meses** [21 MAI 2018]



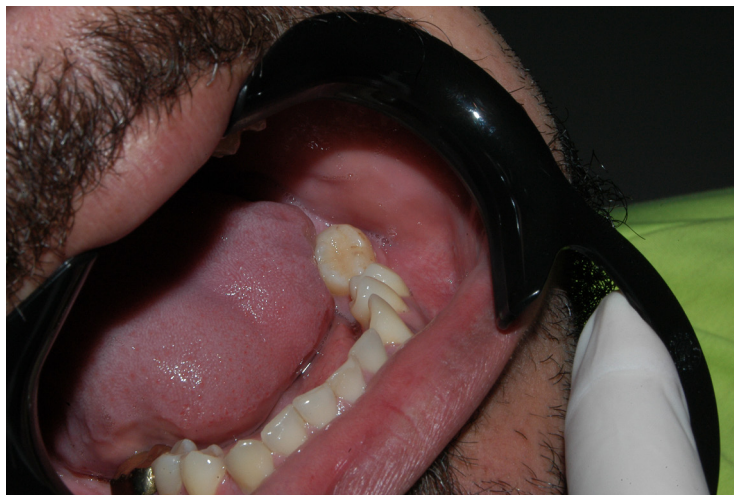Follow Up **≈ 15 meses** [21 MAI 2018]



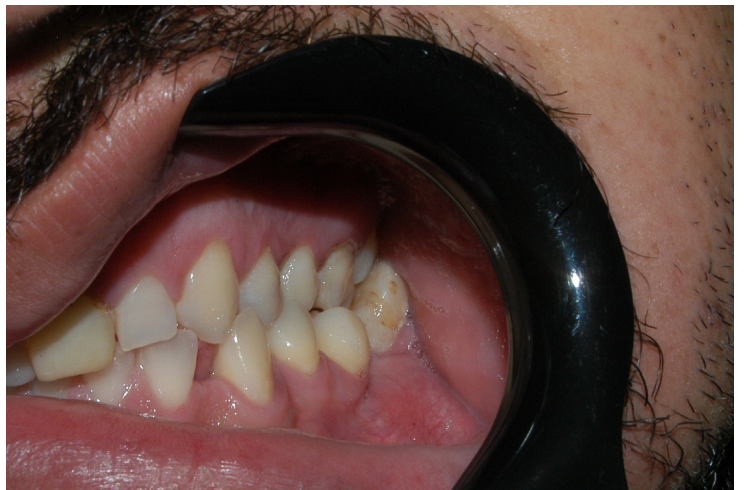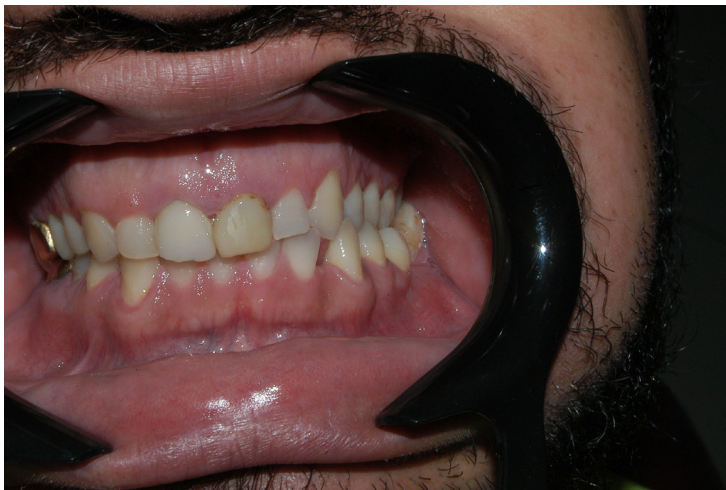Follow Up \approx **15 meses** [21 MAI 2018]



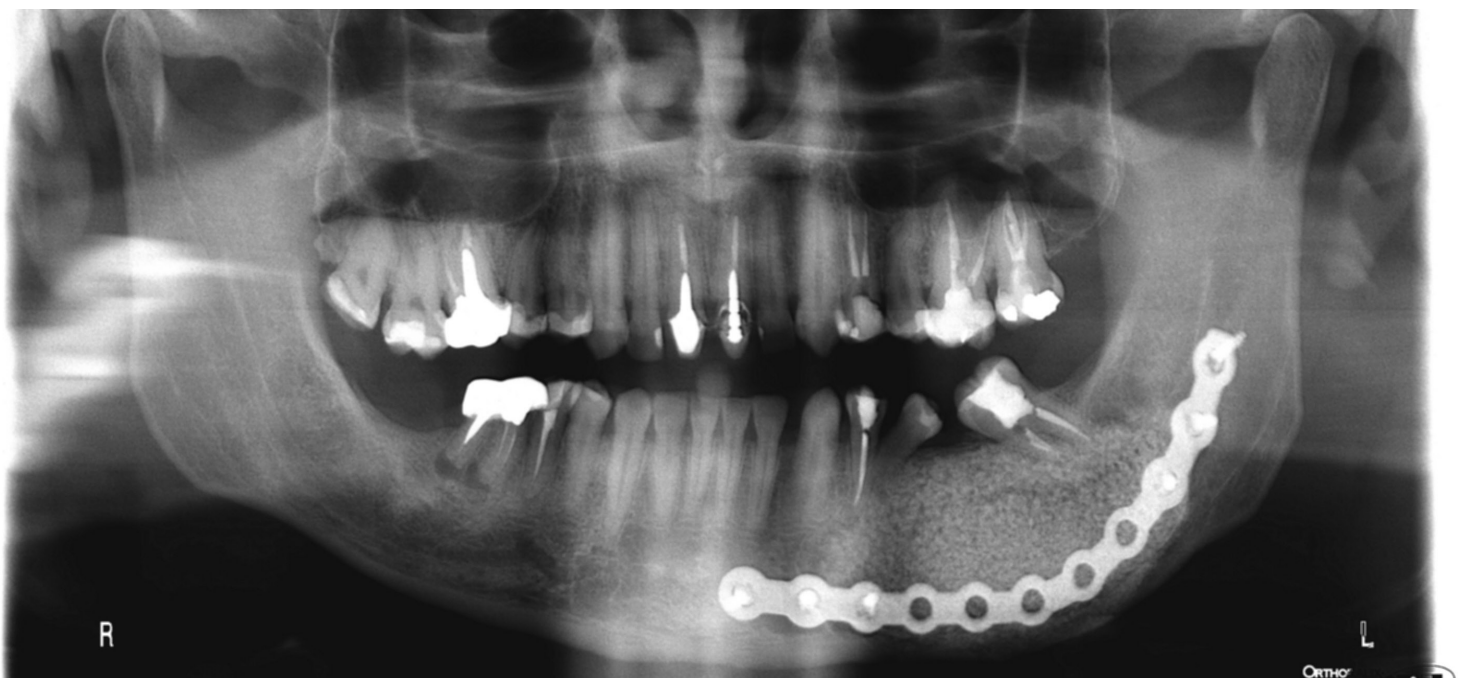
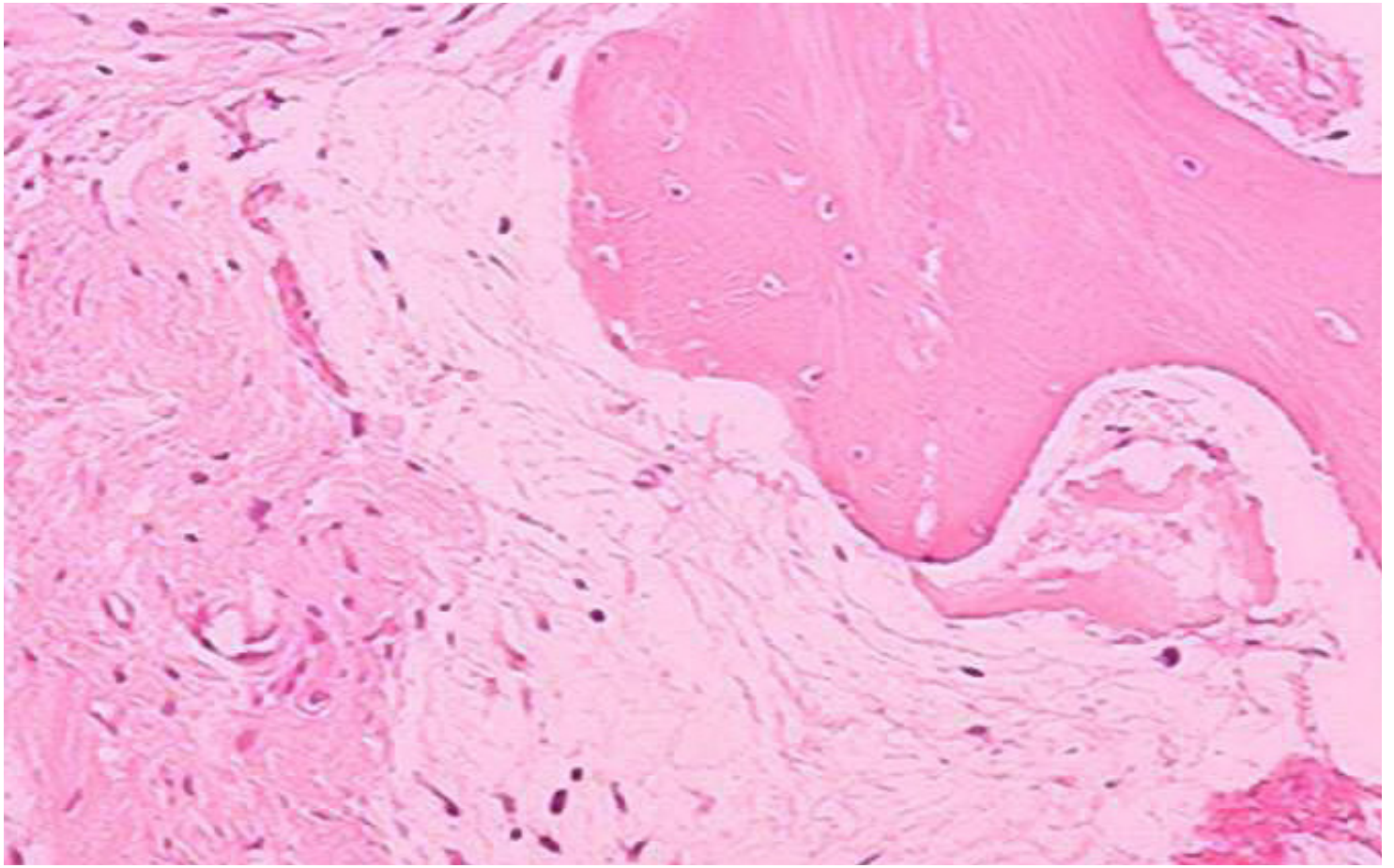
Follow Up \approx **15 meses** [21 MAI 2018]



Follow Up \approx **2 anos** [27 FEV 2019]



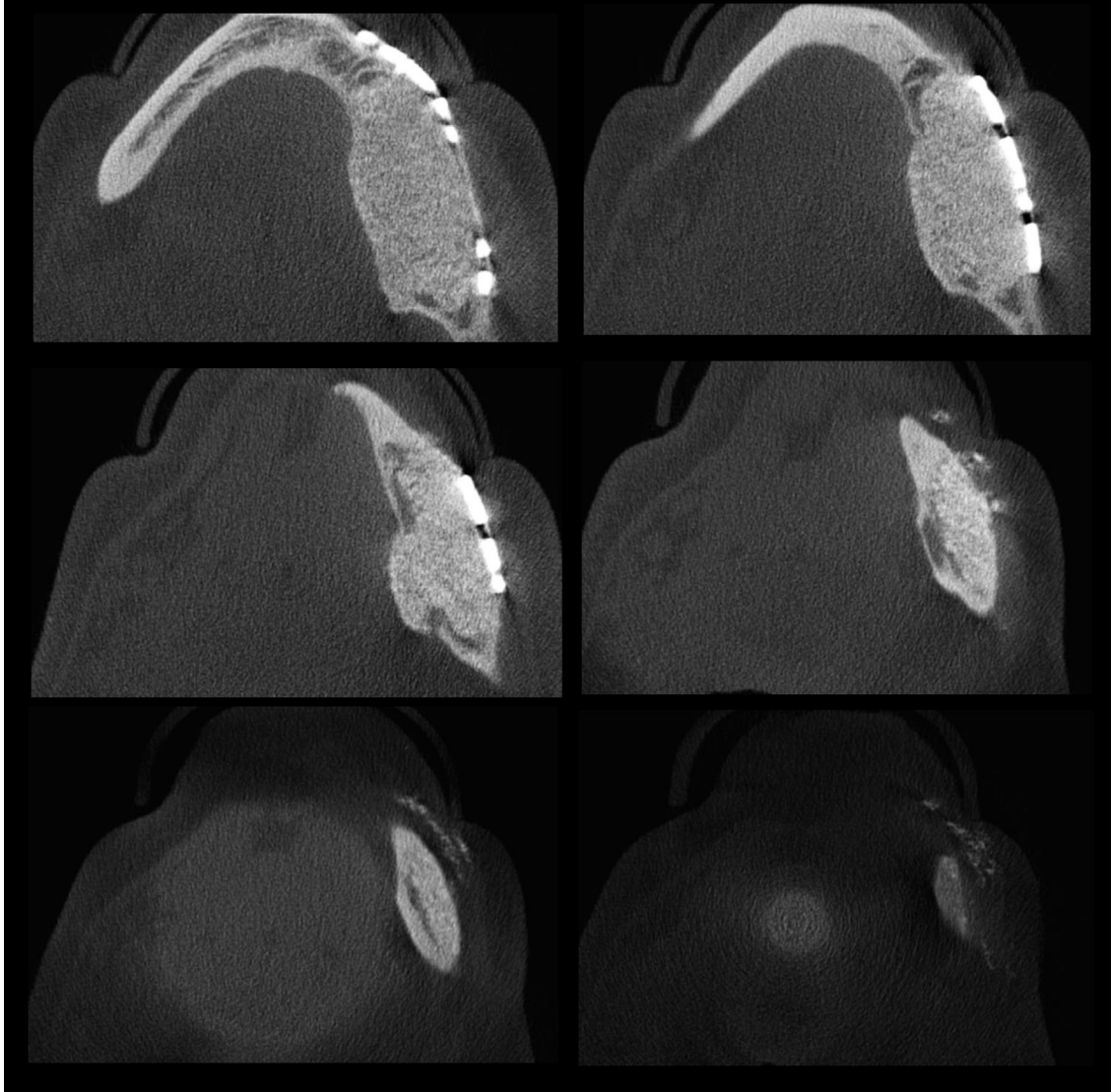
Follow Up \approx **2 anos** [27 FEV 2019]



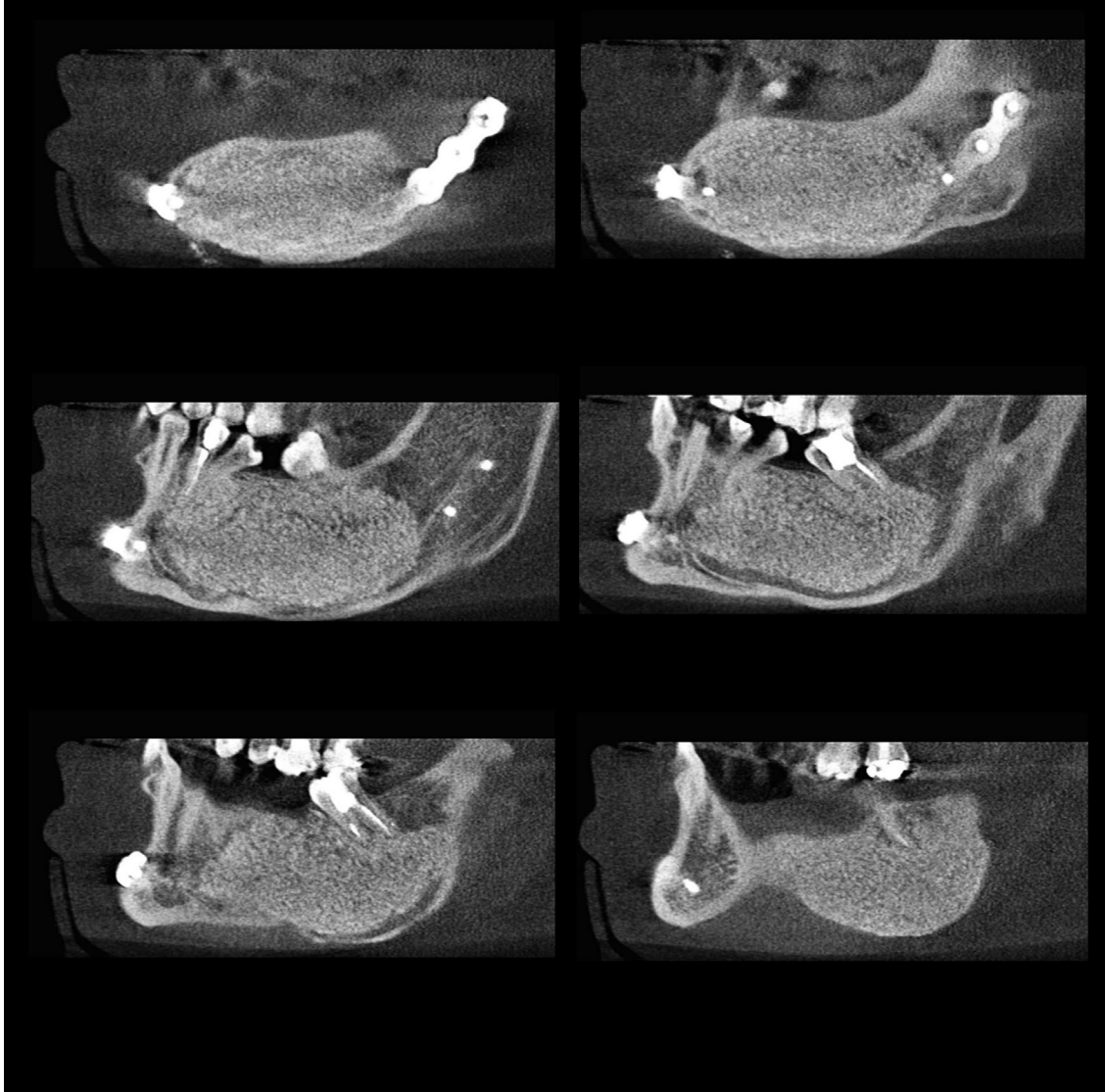
Follow Up ≈ **02 anos** [14 MAR 2019]



Folha: 9



Follow Up ≈ **02 anos** [14 MAR 2019]



Follow Up ≈ **02 anos** [14 MAR 2019]



Prof Daniel NASTRI

Especialista em Cirurgia e Traumatologia Buco Maxilo Facial pelo CFO e SOBRACIBU
Especialista em Disfunção Têmporo Mandibular e Dor Orofacial pelo CFO
Presidente da SOBRACIBU durante as gestões 2013-2015 e 2015-2017