



CASE 51

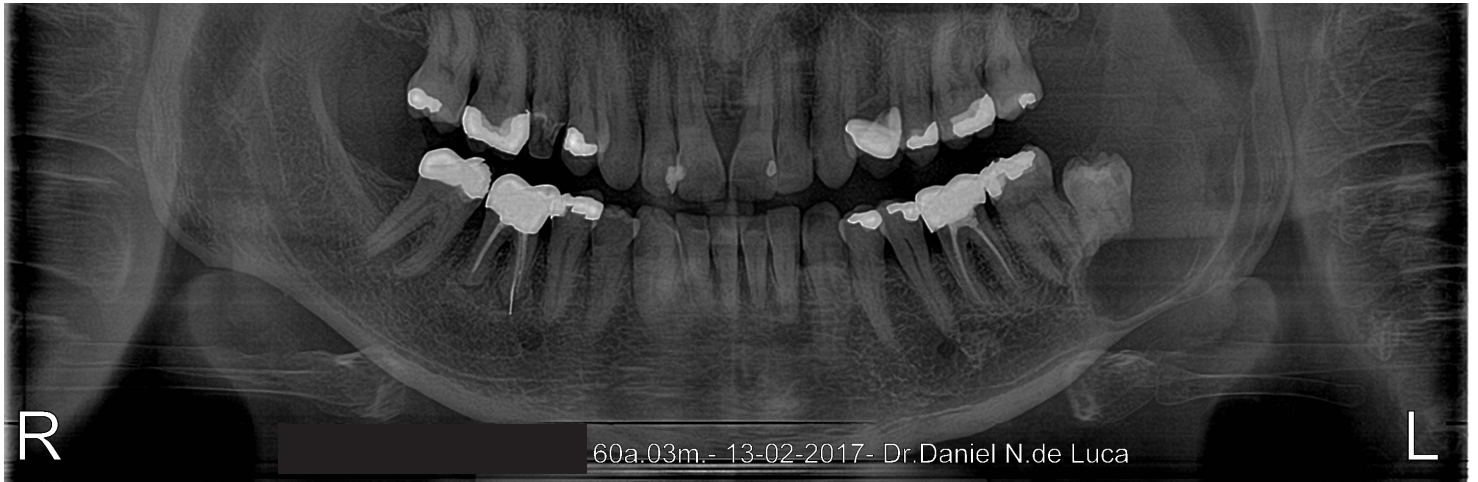Cirurgião: **DANIEL NASTRI DE LUCA**

Diagnóstico: Cisto Dentígero em Mandíbula [Dentigerous Cyst in Mandible]

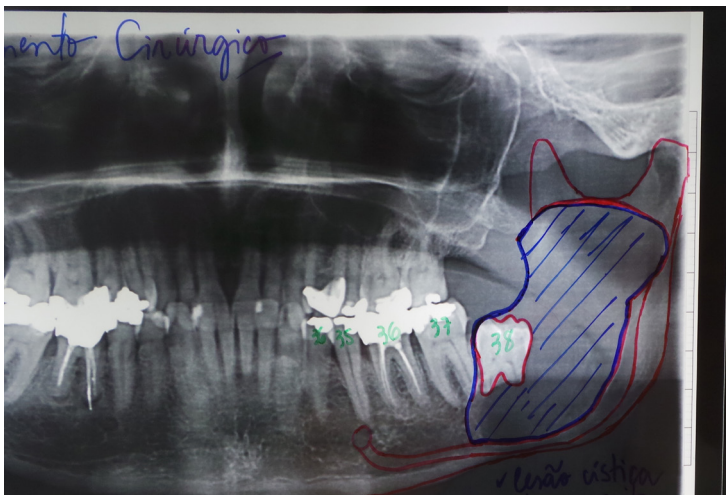
Histórico: Paciente encaminhado para avaliação de lesão em ramo mandibular E. Começou a sentir dores em dentes anteriores da mandíbula há 6 meses. Nega parestesia do NAI.

Exérese de Cisto Mandibular e Colocação de Placa com Enxerto Ósseo e Membrana de L-PRF

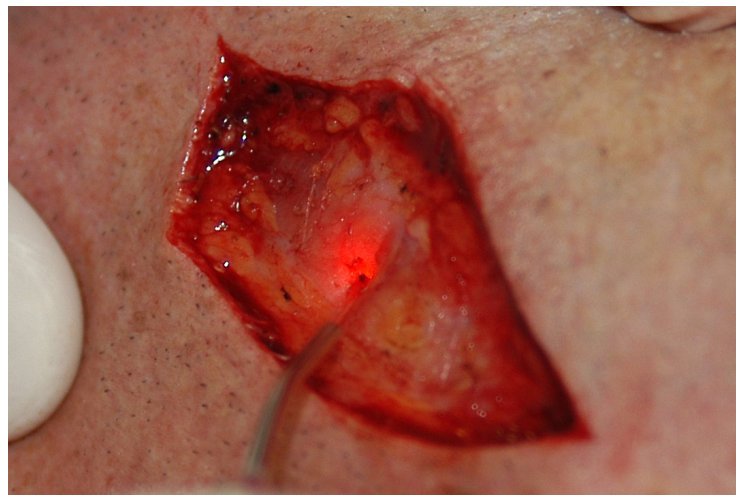Paciente: P.T.C, 60 anos, sexo masculino



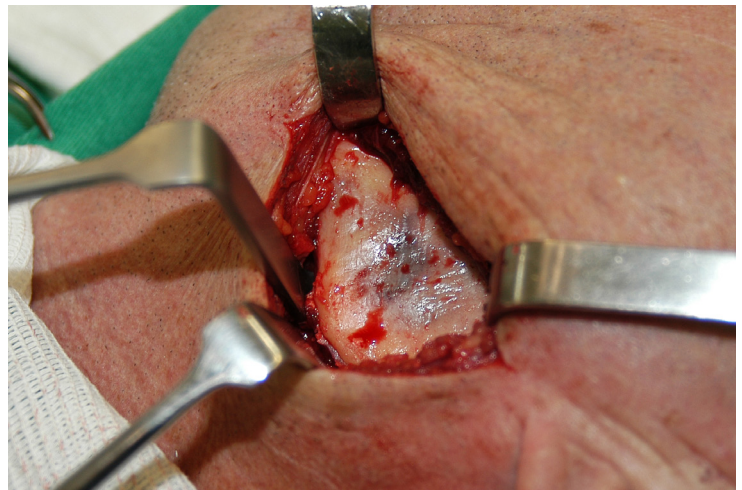
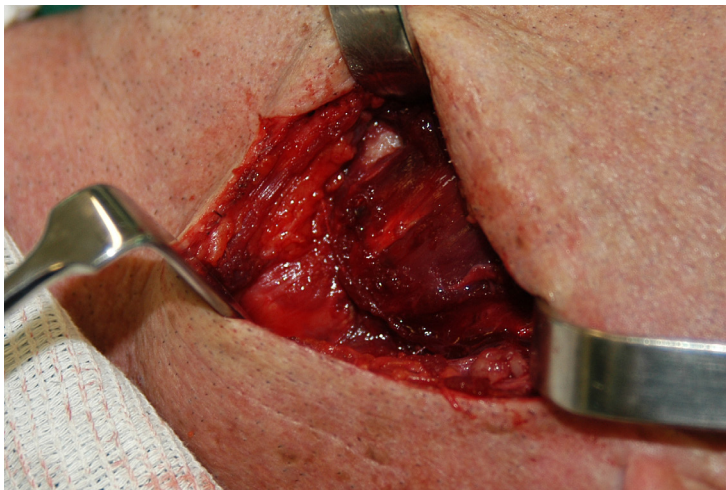
Radiografia Inicial [13 FEV 2017]

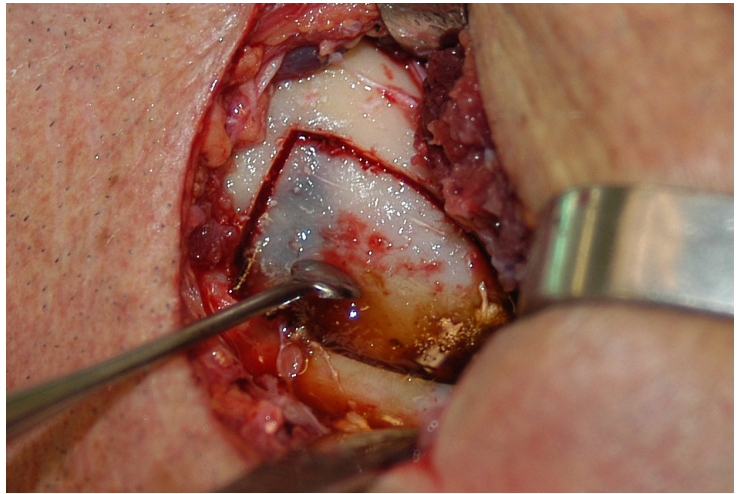
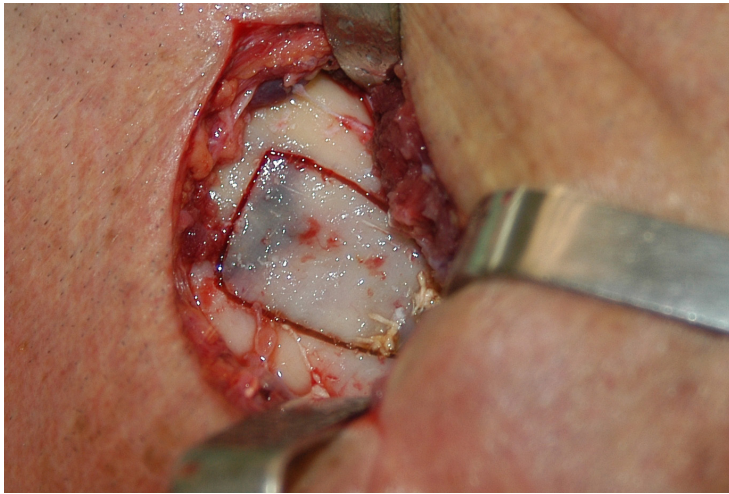


Cirurgia [17 FEV 2017]



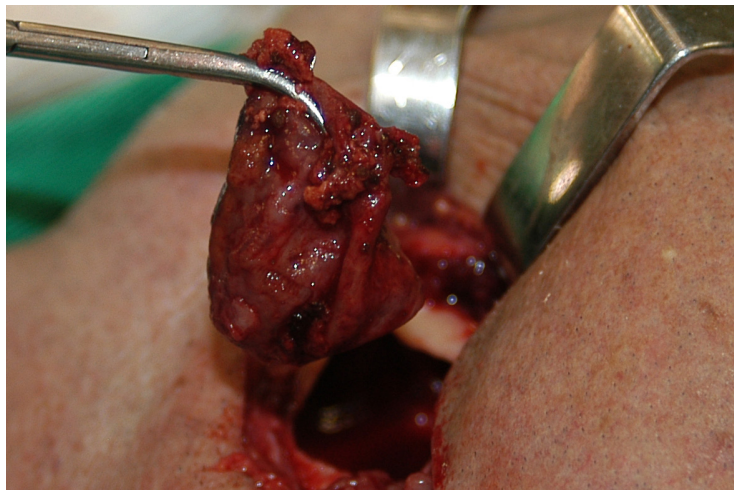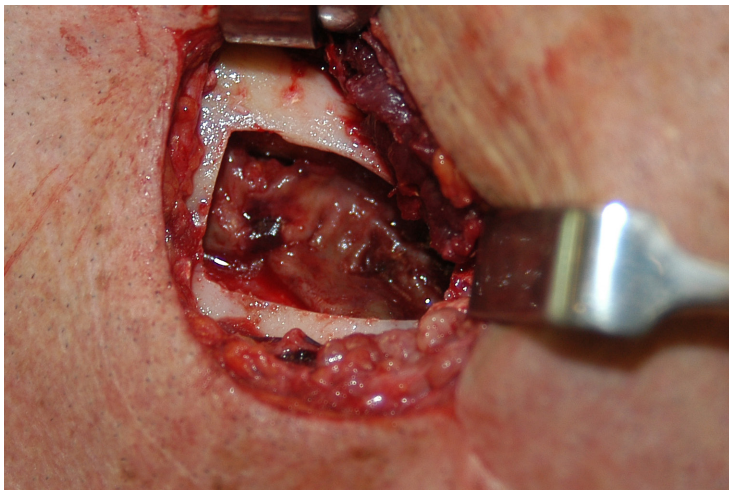
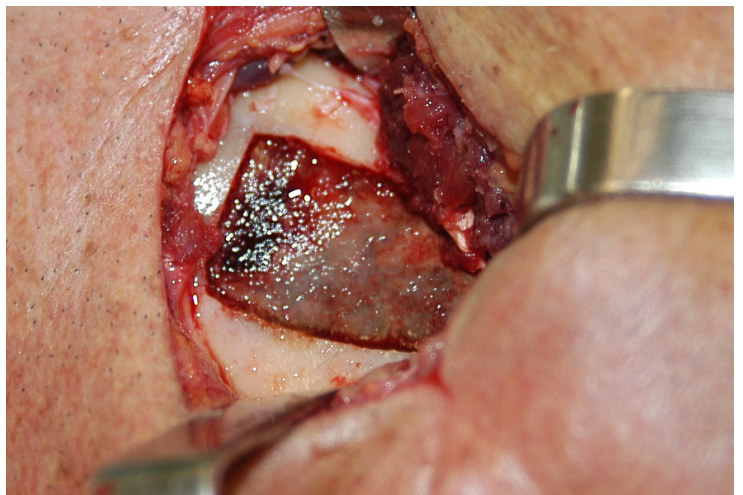
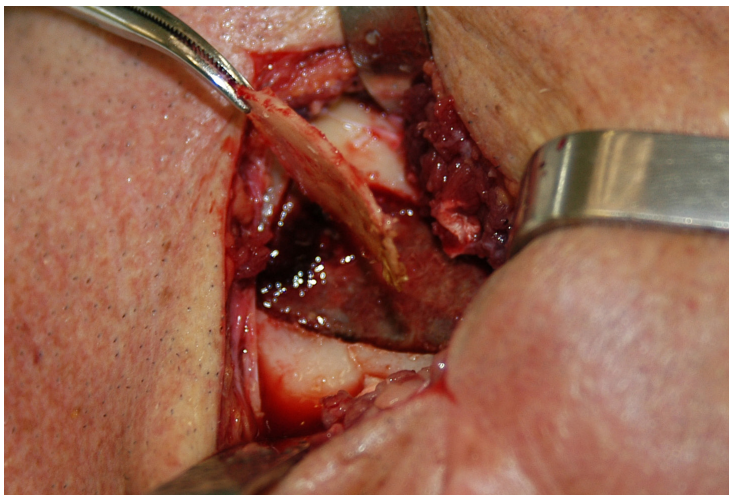
Acesso cirúrgico com laser de alta potência (Marca DMC)



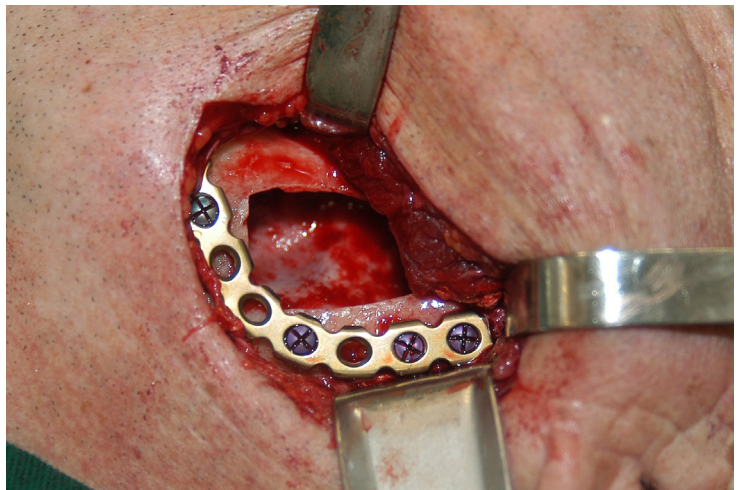
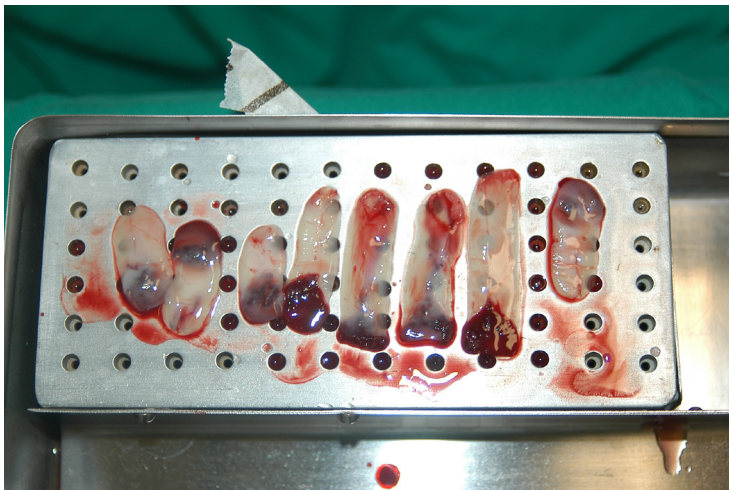
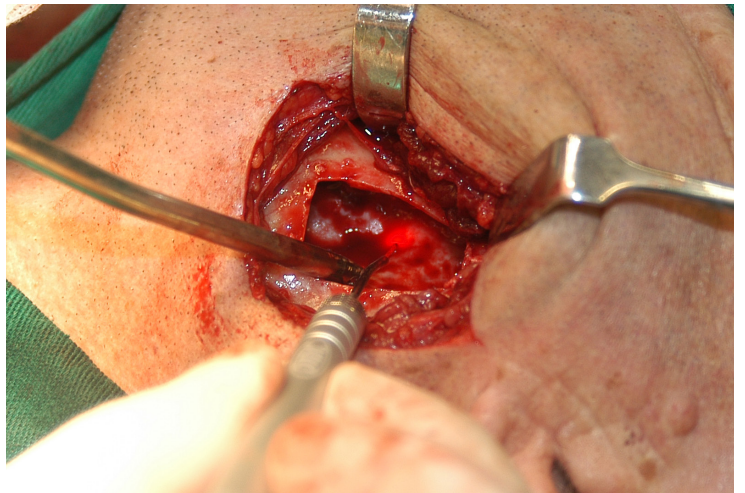
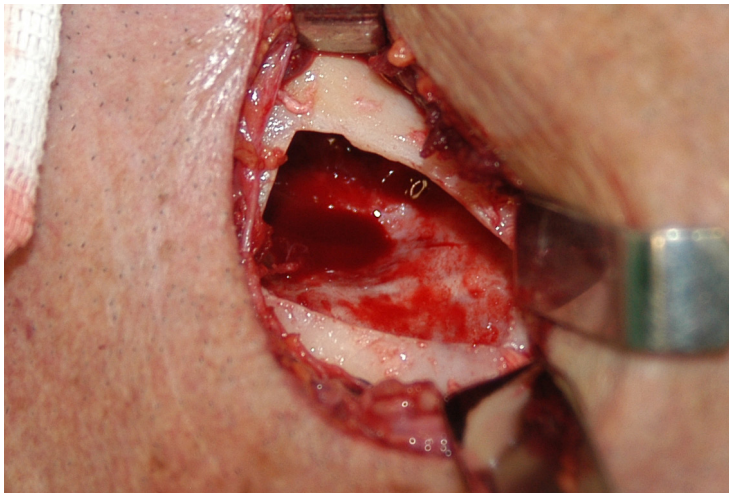
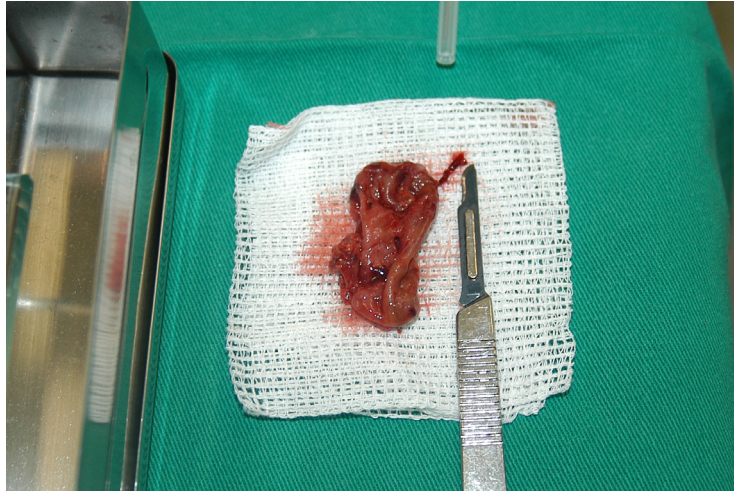
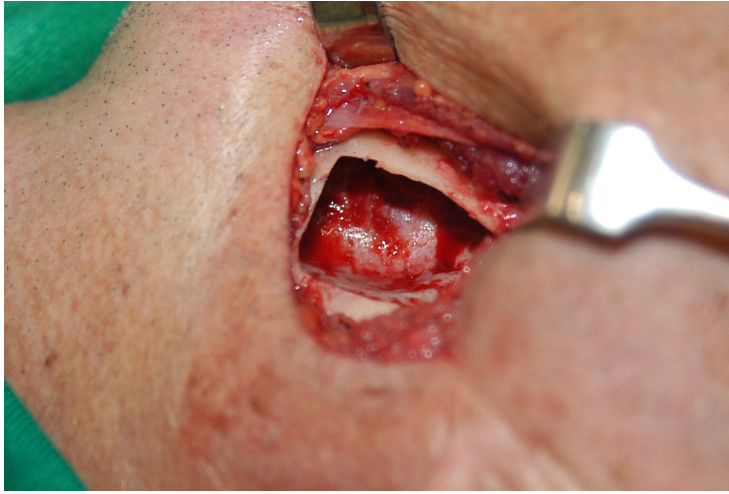


Osteotomia com Piezocirurgia

Piezoelectric bony window Osteotomy



Exérese Total da Membrana Cística

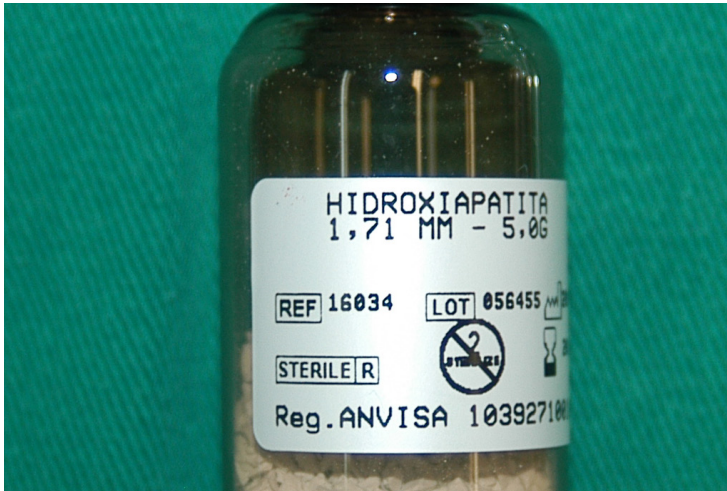


Membranas de L-PRF

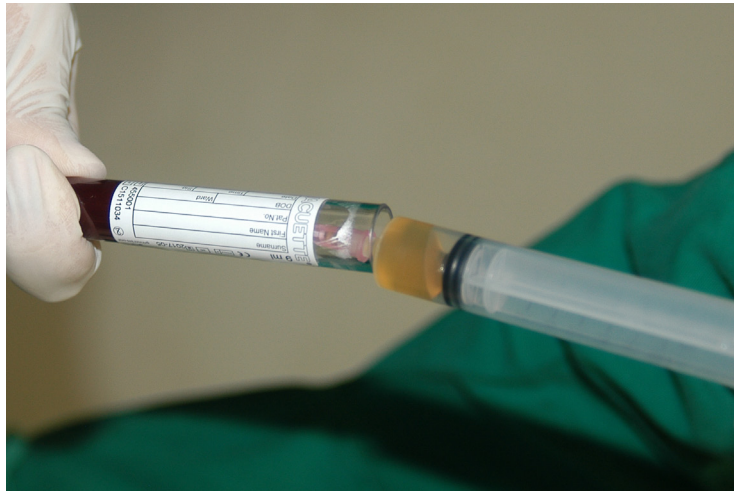
L-PRF membranes

Colocação de placa e parafuso de fixação

Mini-plates/screws placed



Hidroxiapatita [Cod 16034 Lote 056455]

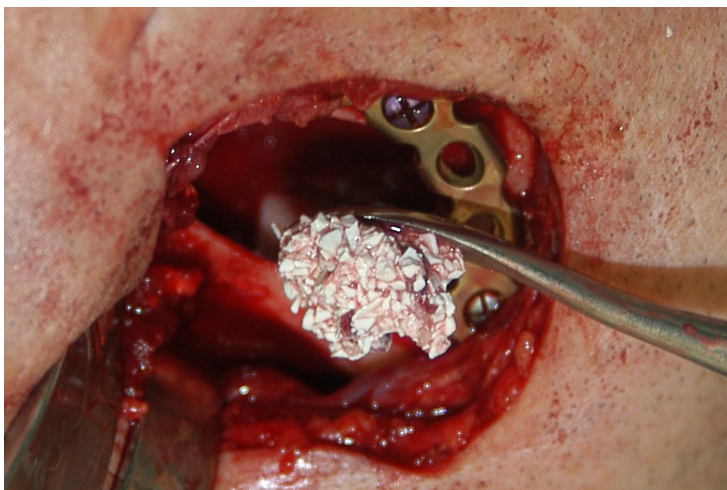


I-PRF



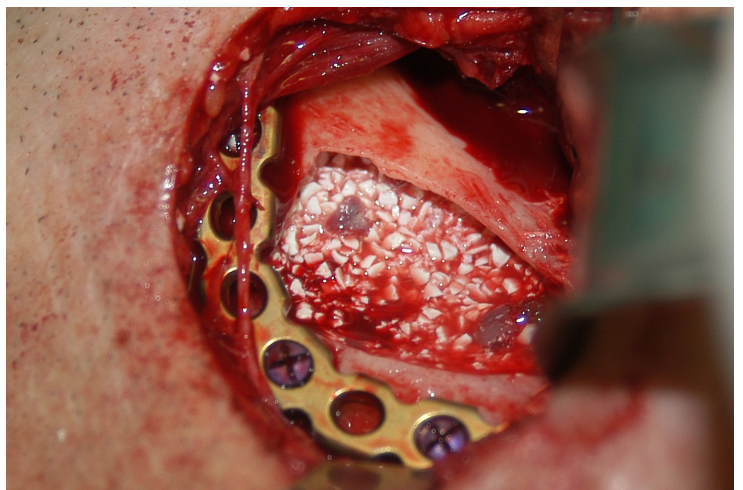
Preparação do Sticky Bone

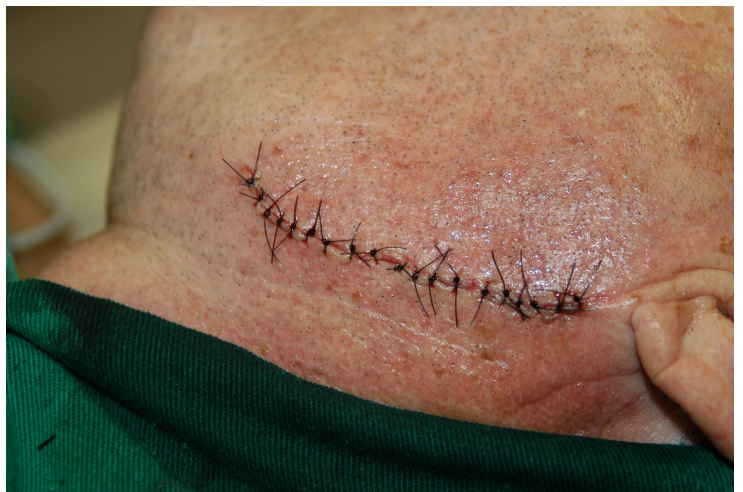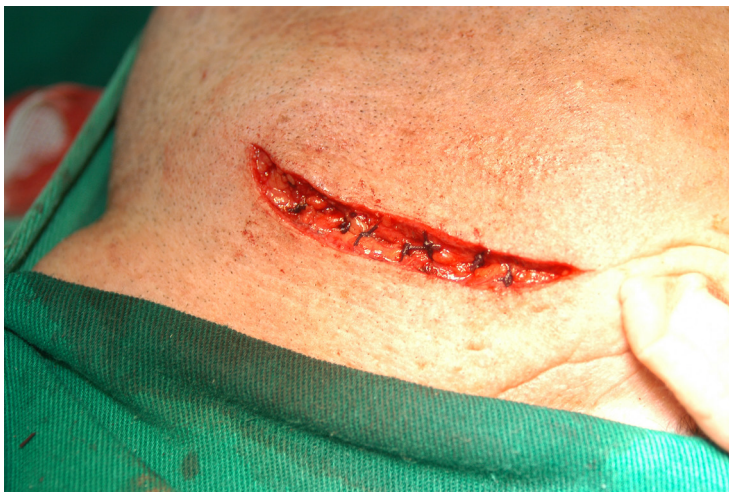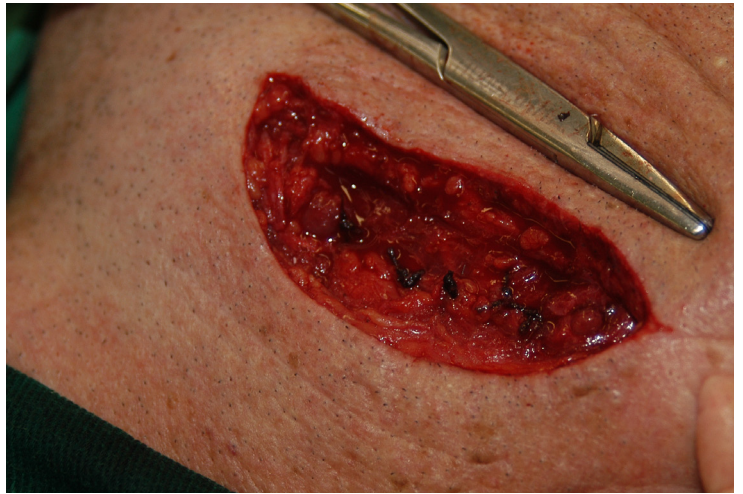
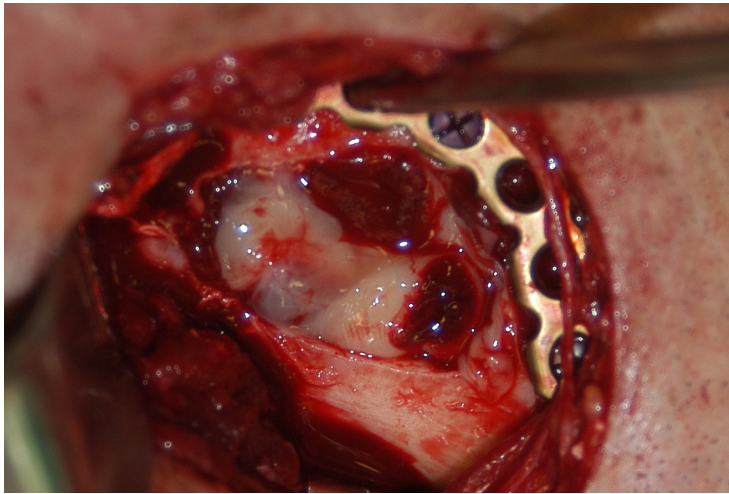
Procedure to prepare sticky bone



Cavidade preenchida com Hidroxiapatita

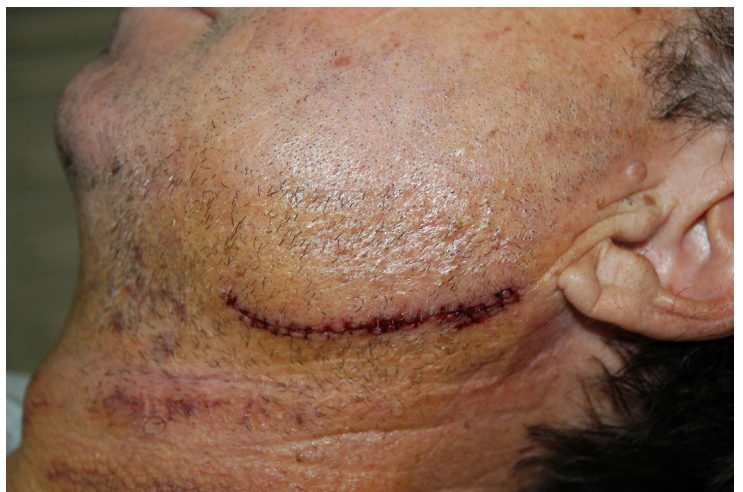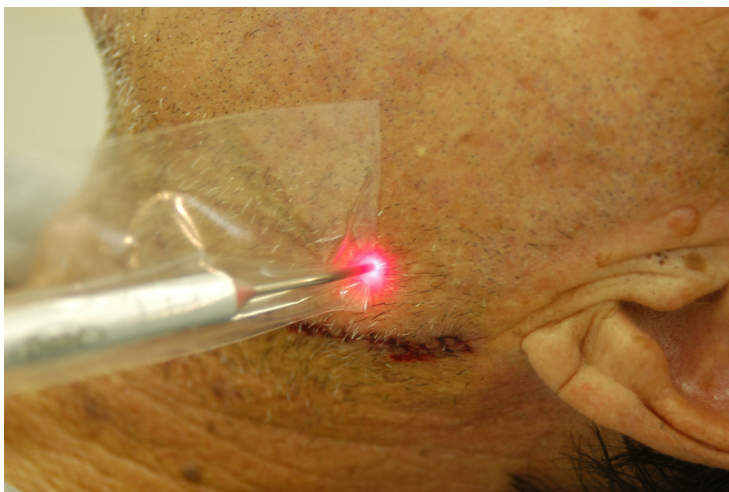The cavity is filled with Hydroxyapatite





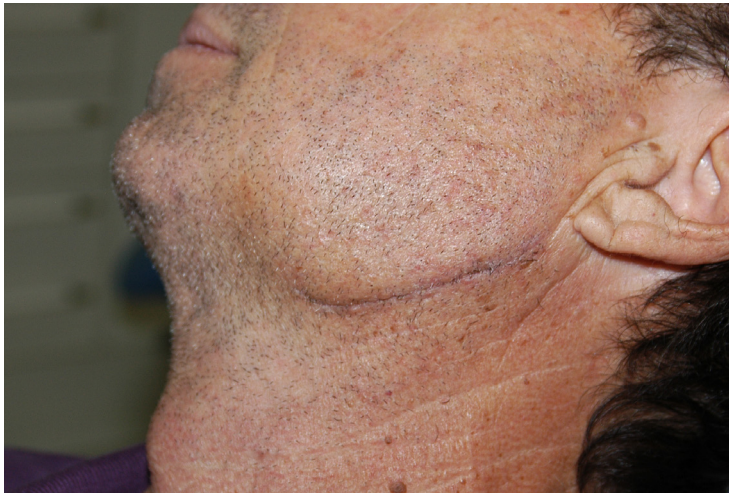Fechamento e sutura

Final suturing and closing

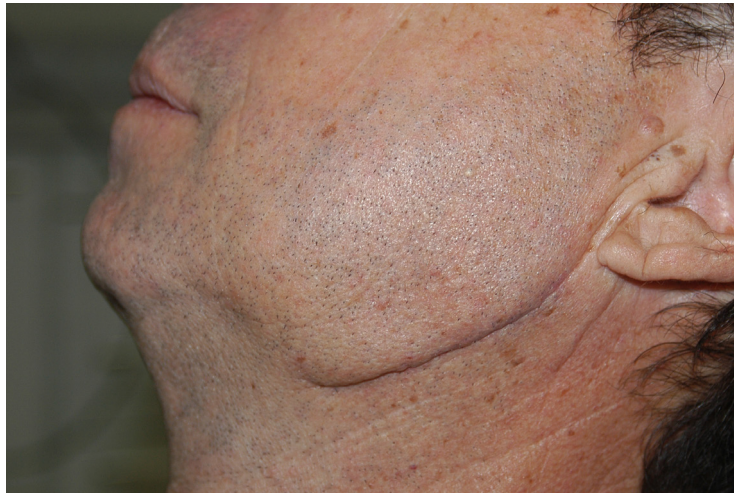

Laserterapia imediata [17 FEB 2017]

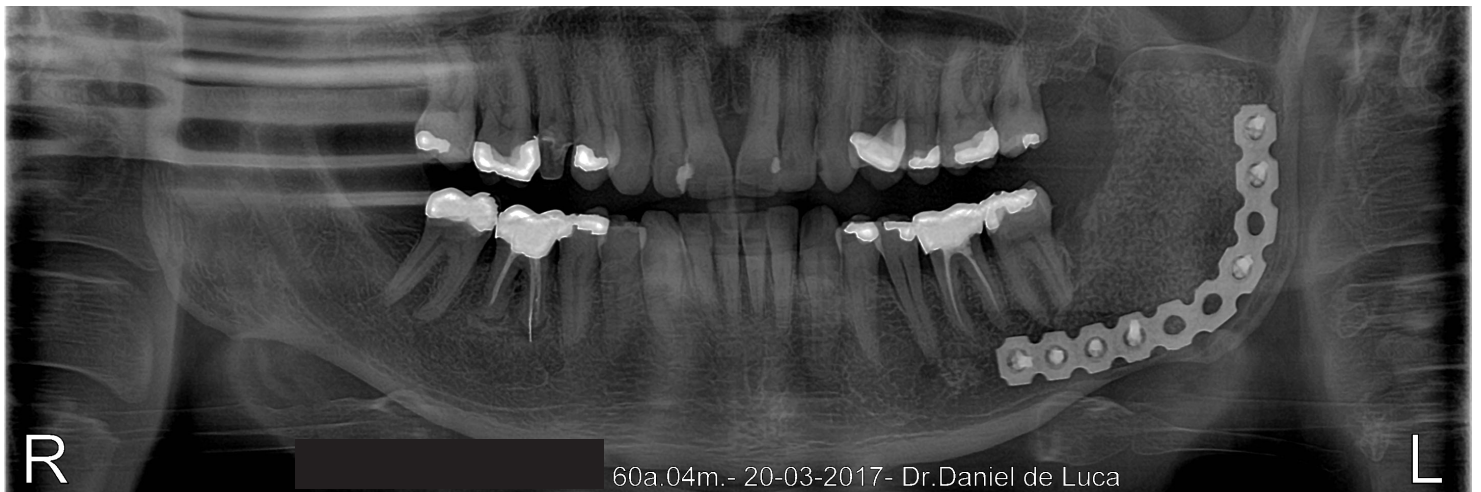Laser therapy was performed immediately after the procedure



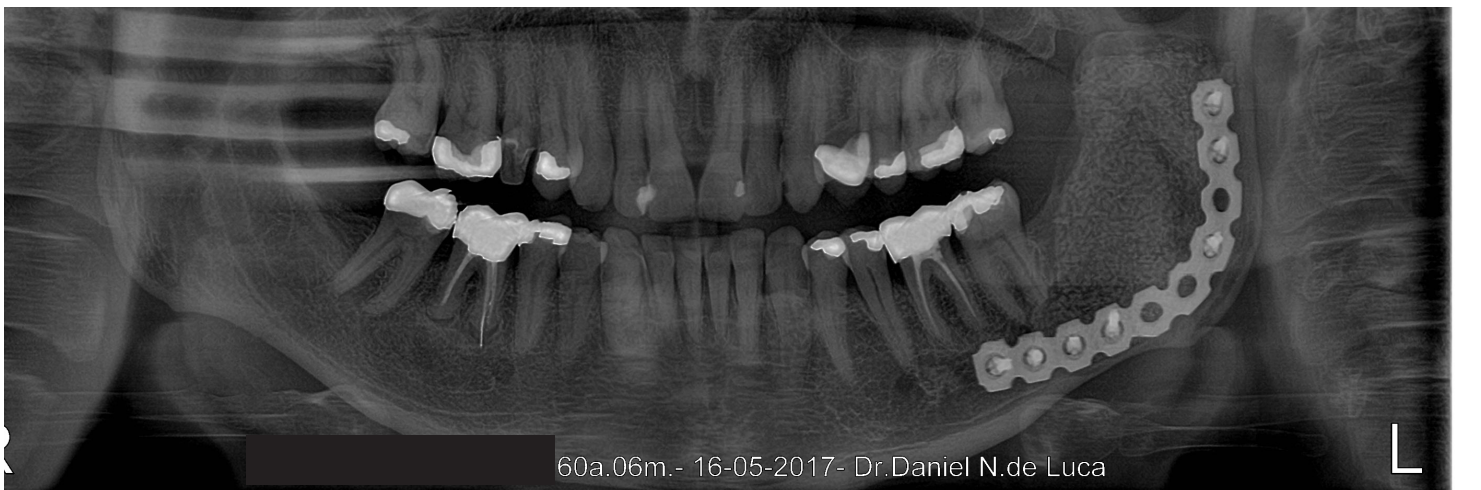Follow Up **13 dias** [02 MAR 2017]



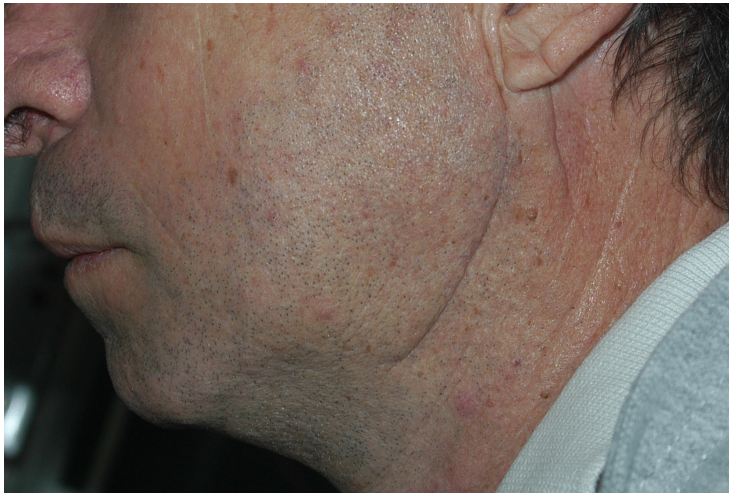Follow Up **28 dias** [17 MAR 2017]



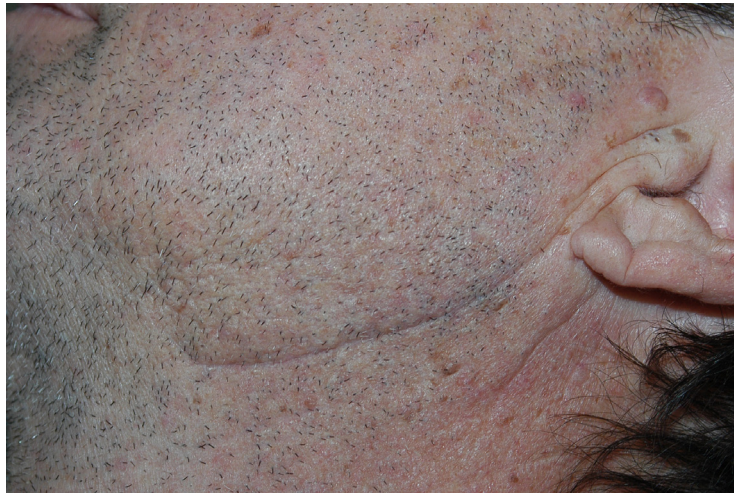Follow Up **31 dias** [20 MAR 2017]



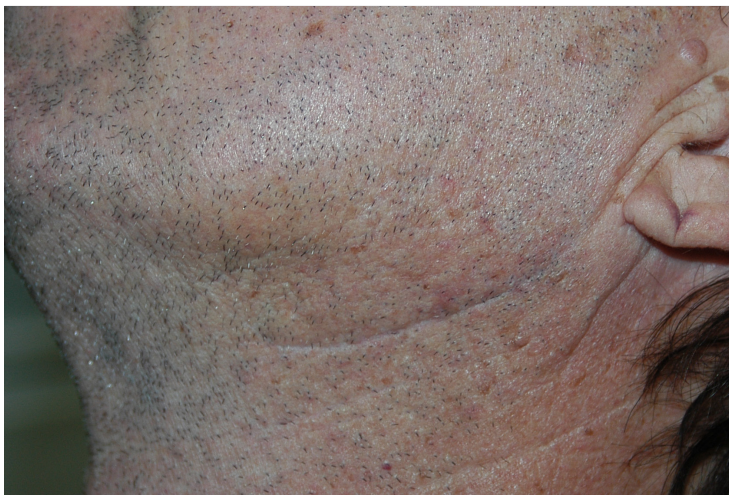Follow Up **88 dias** [16 MAI 2017]



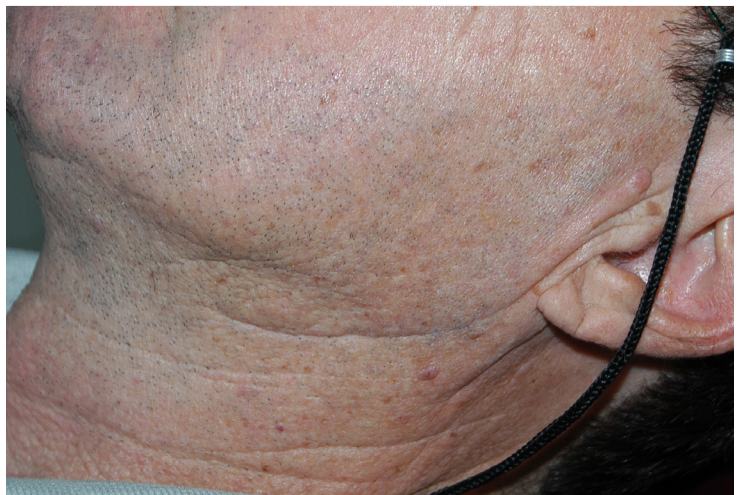Follow Up **59 dias** [17 ABR 2017]



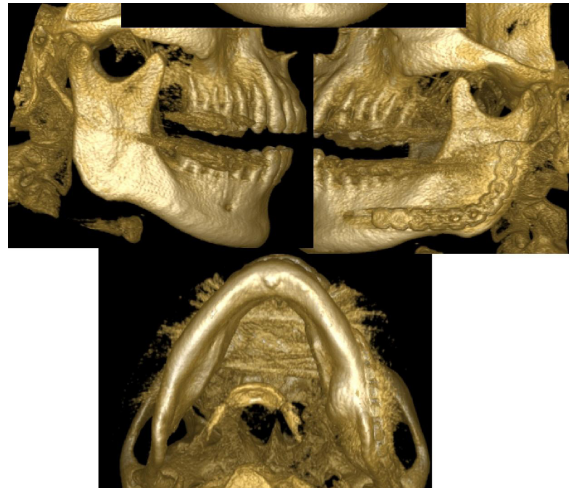
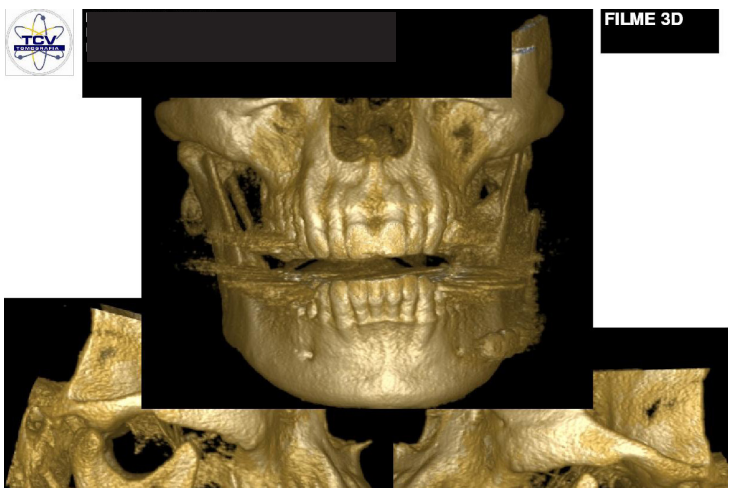
Follow Up **89 dias** [17 MAI 2017]

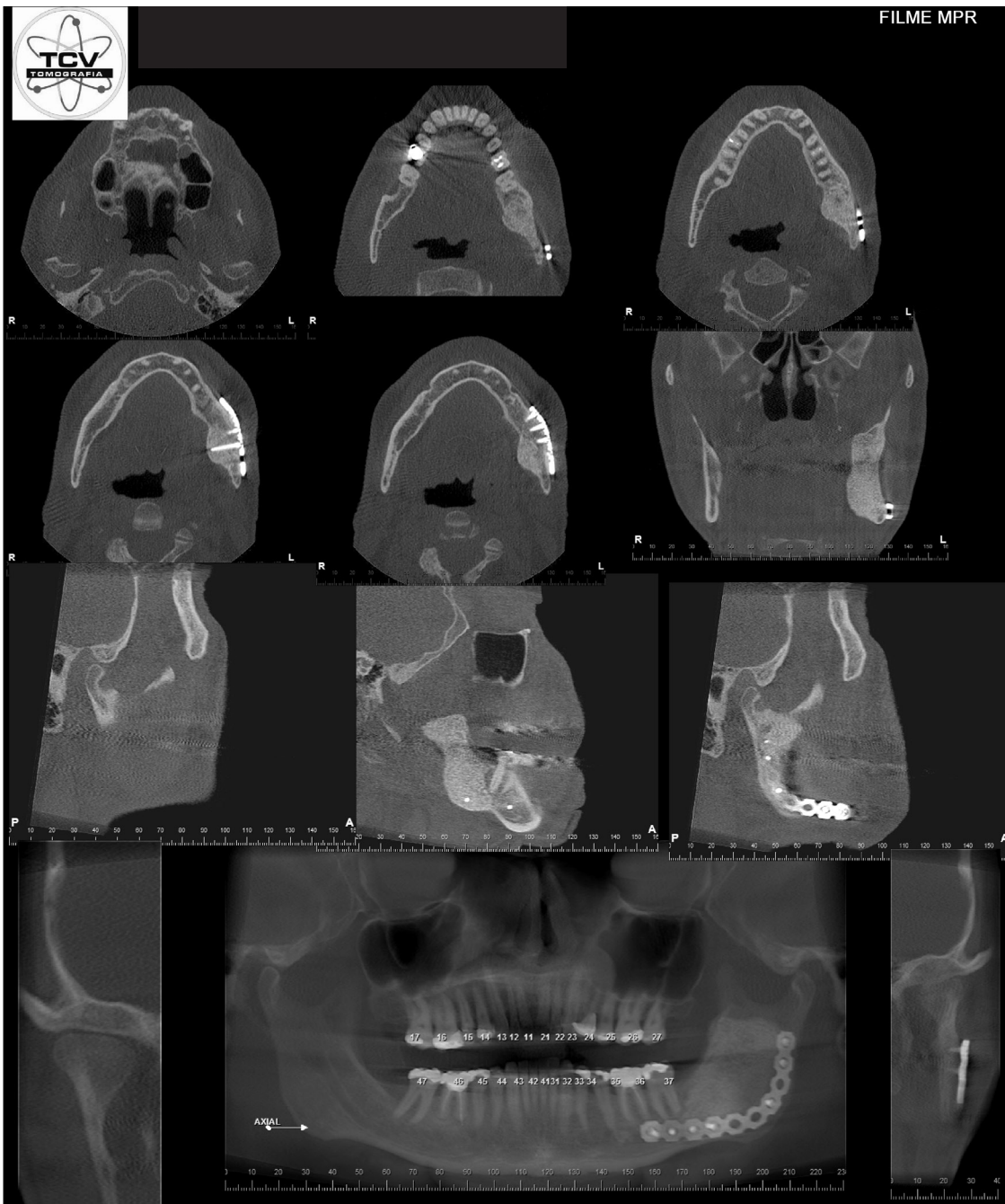

Follow Up **09 meses** [14 NOV 2017]



Follow Up **15 meses** [09 MAI 2018]





Follow Up **15 meses**



Prof Daniel **NASTRI**

Especialista em Cirurgia e Traumatologia Buco Maxilo Facial pelo CFO e SOBRACIBU

Especialista em Disfunção Têmporo Mandibular e Dor Orofacial pelo CFO

Presidente da SOBRACIBU durante as gestões 2013-2015 e 2015-2017