



## CASE 48

---

Cirurgiões: Claudia **TAGATA**, Kelson **OLIVEIRA** e Marcelo **FAVERI**

---

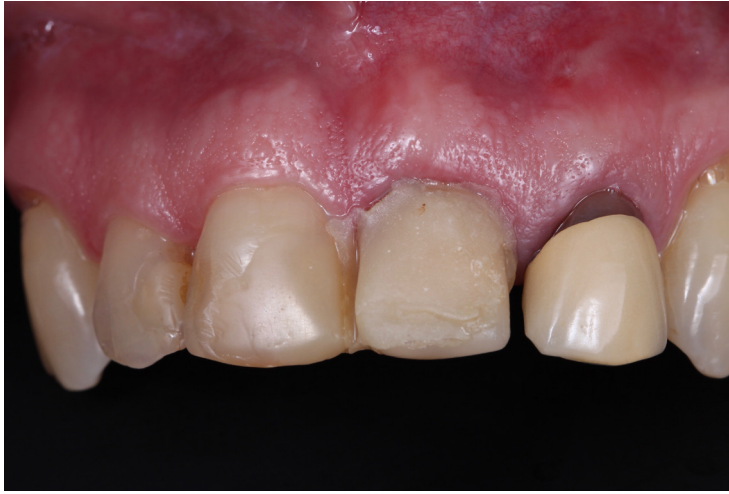**Diagnóstico:**

---

**Paciente:** N.G.R. 64 anos, sexo masculino

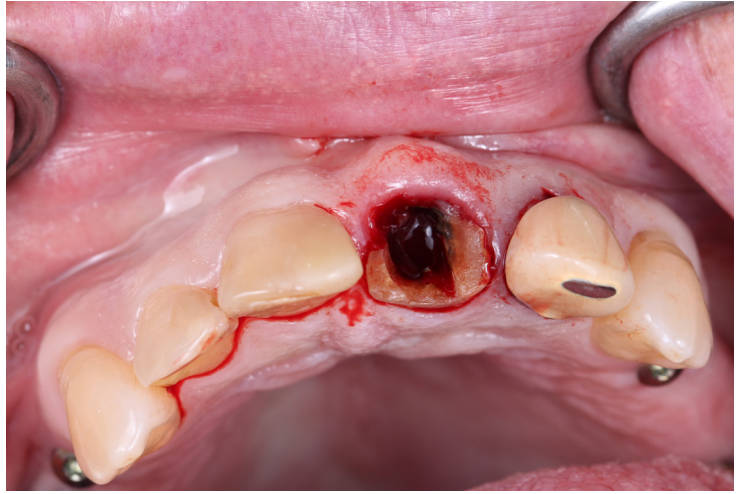
---

Follow Up ≈ **12 meses**



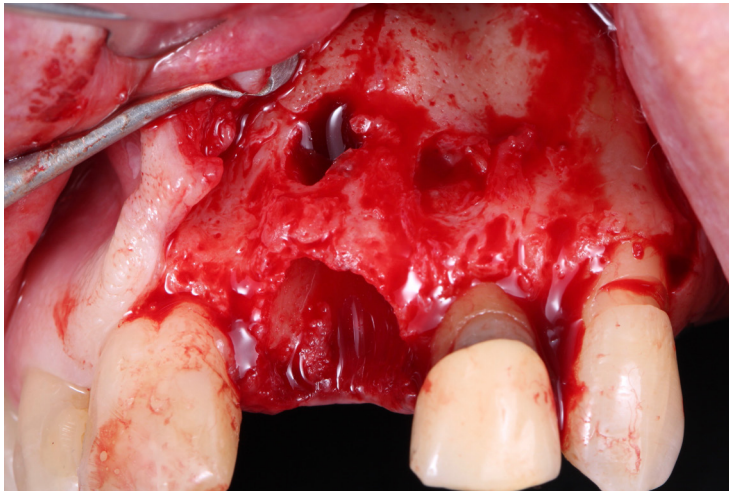
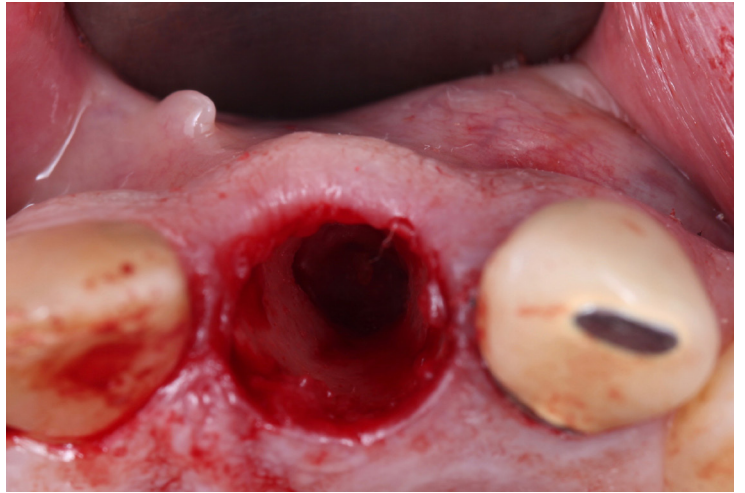
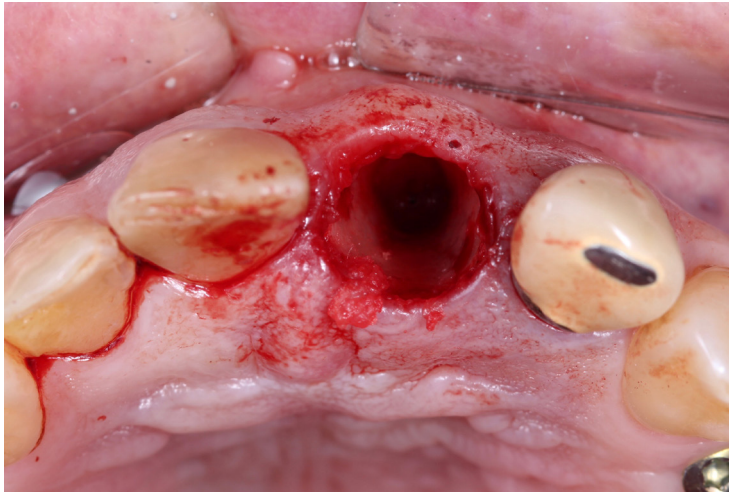**Situação clínica pré-operatória**

Clinical situation pre-operatively



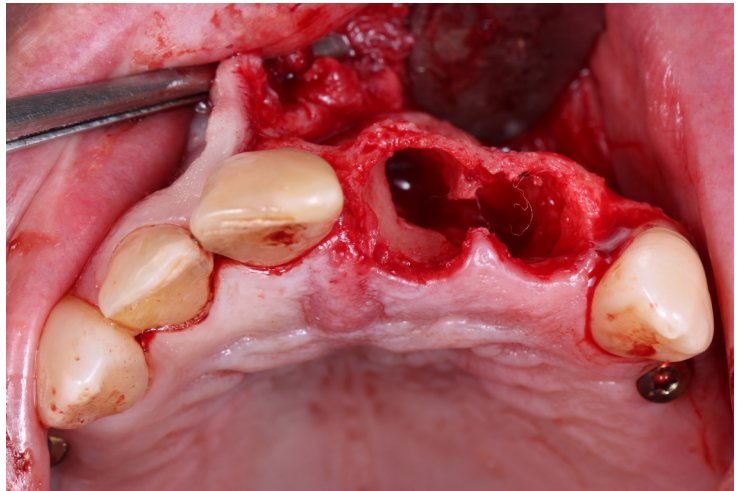
**Vista oclusal**

Occlusal View



**Osso vestibular**

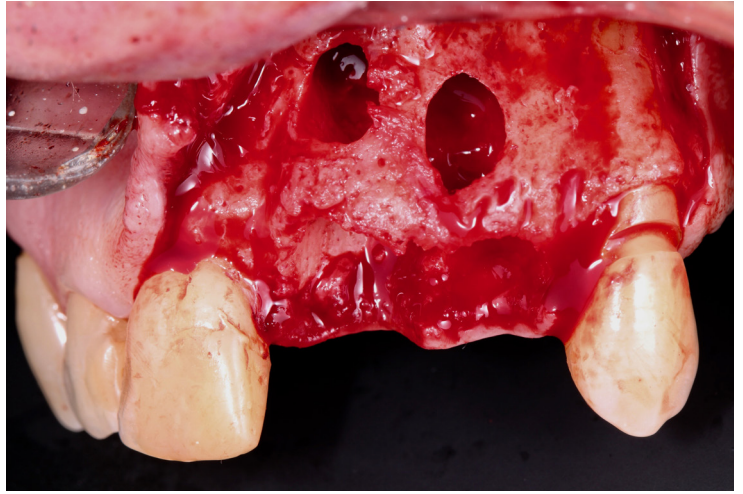
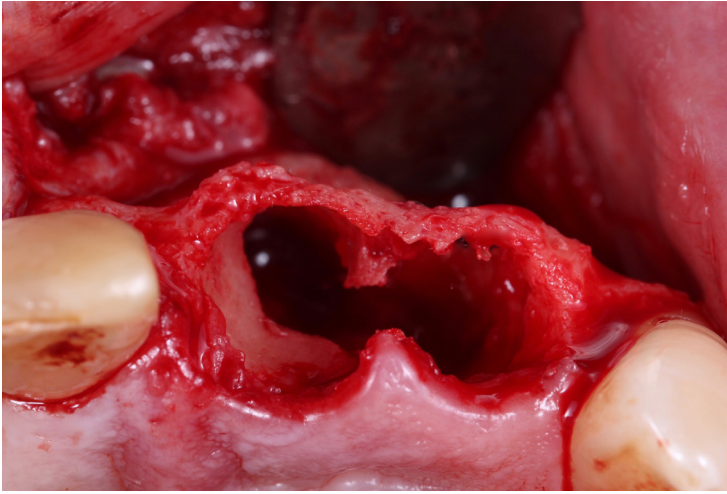
Vestibular Bone defect



**Osso bucal**

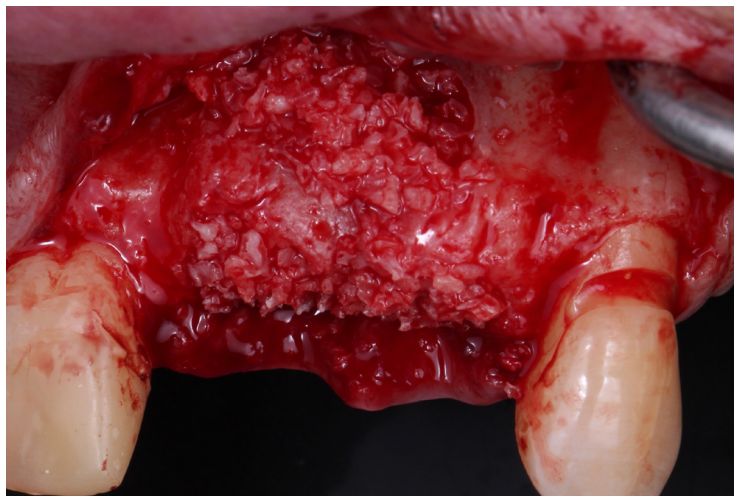Buccal Bone





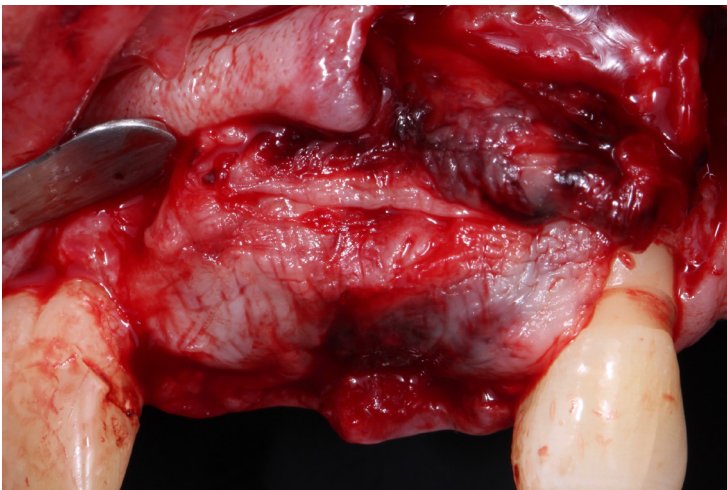
### Defeito Ósseo Vertical

Vertical bony defects



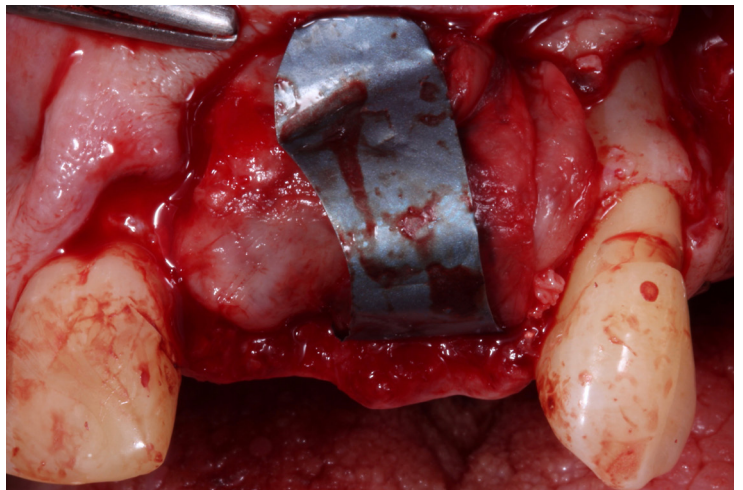
### Enxerto ósseo Bonefill Porous [Cod 16892 Lote 058822]

Bonefill Porous bone graft



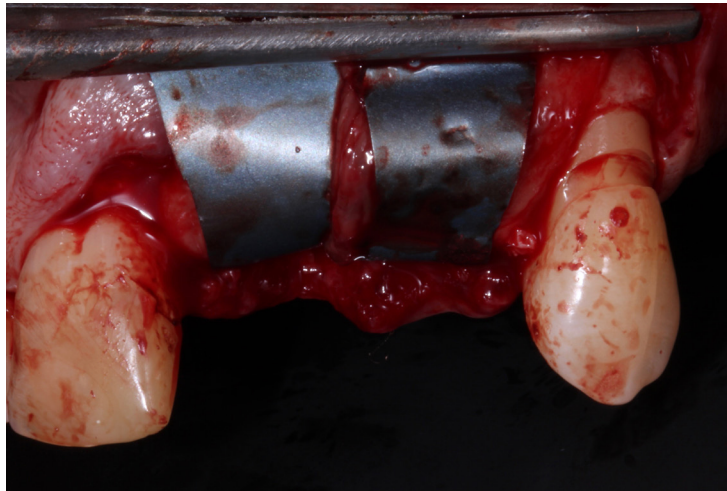
### Membrana de PRF

PRF Membrane



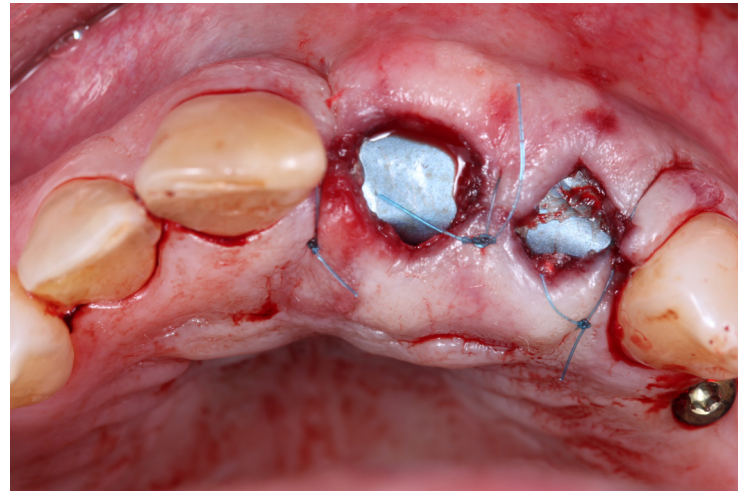
### Surgitime Titânio Seal [Cod 16890 Lote 063876]

Surgitime Titanium Seal



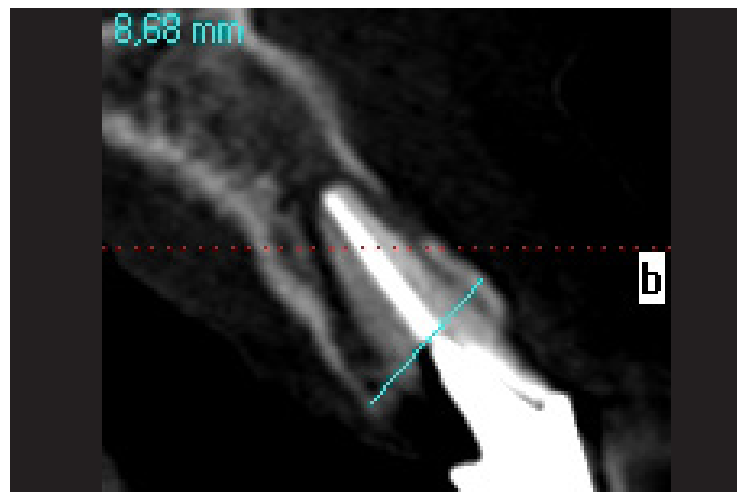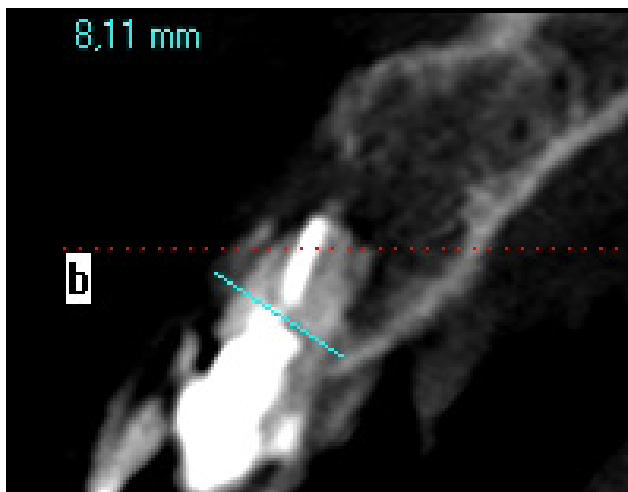
**Defeito estabilizado com Surgitime Titânio Seal**

Defect stabilized with Surgitime Titanium Seal



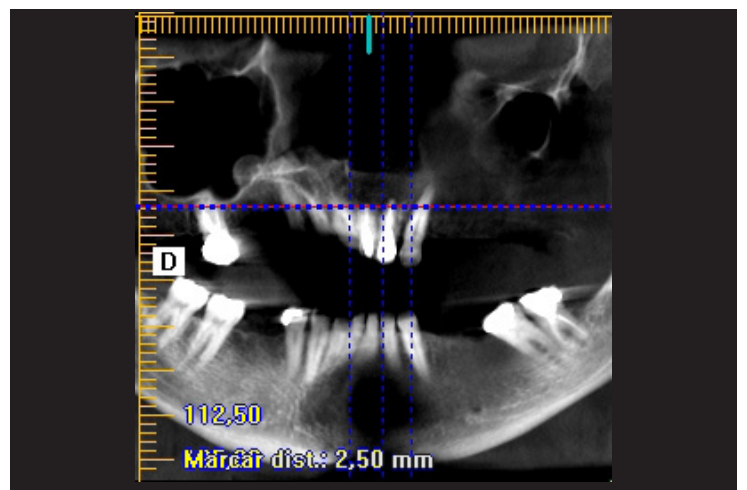
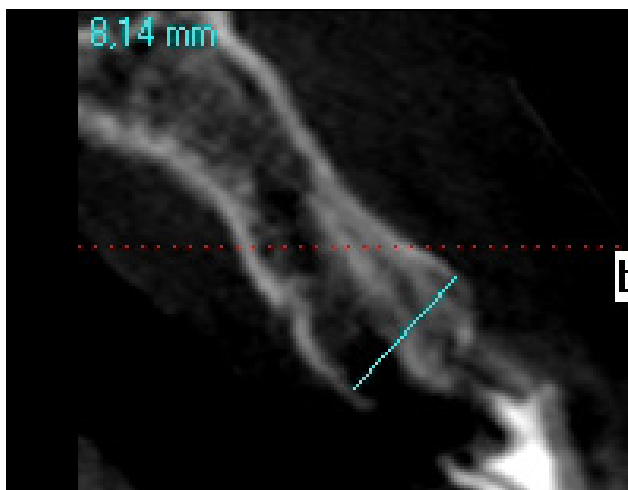
**Surgitime Titânio Seal estabilizada**

Surgitime Titanium Seal stabilized



**PO Imediato [XX XX 2018]**

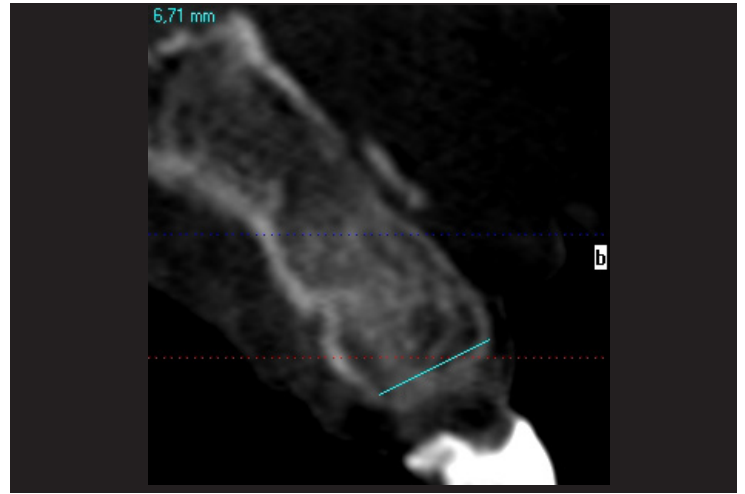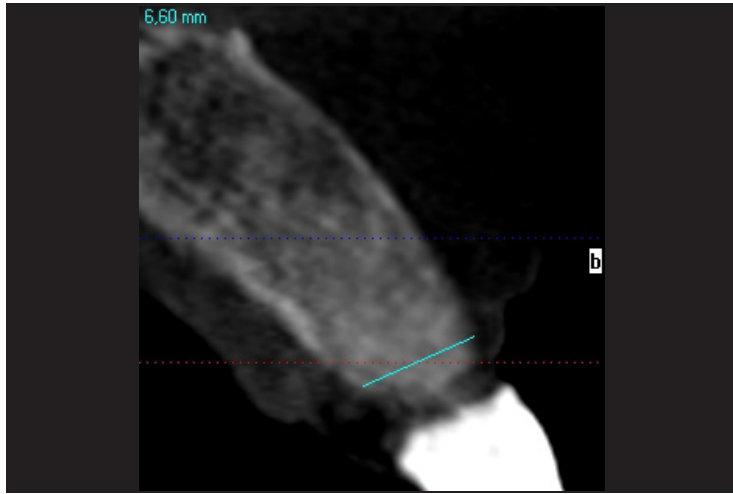
Post-operative radiograph



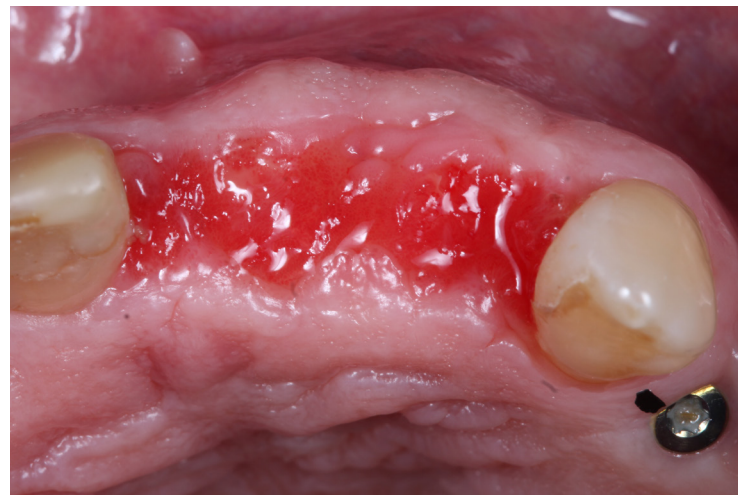
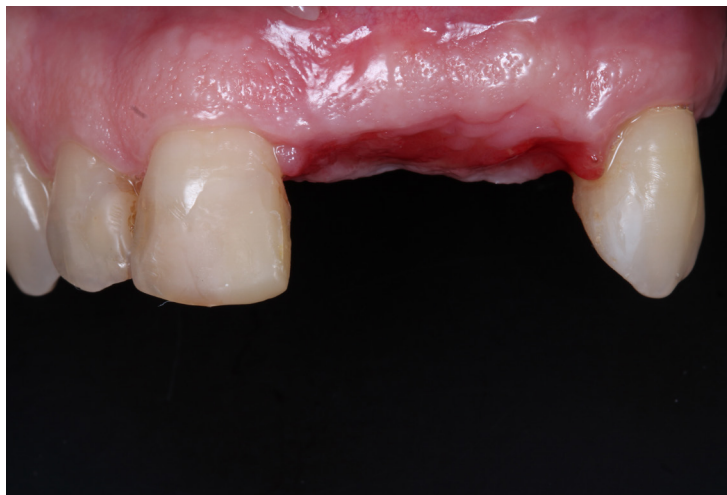**PO Imediato**

Post-operative radiograph

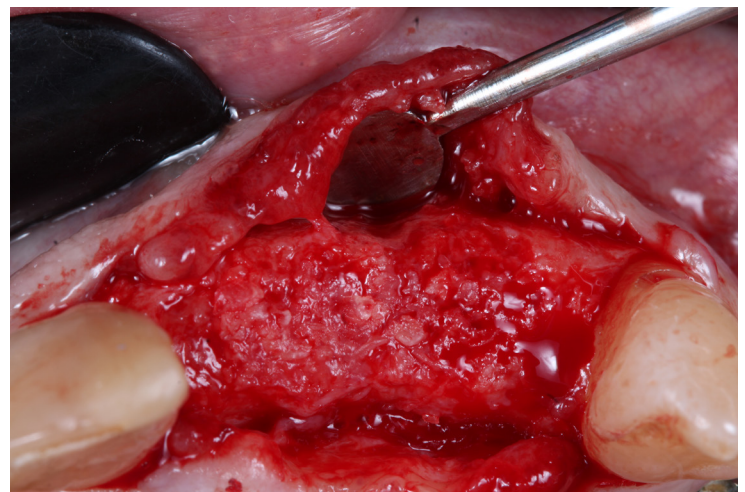
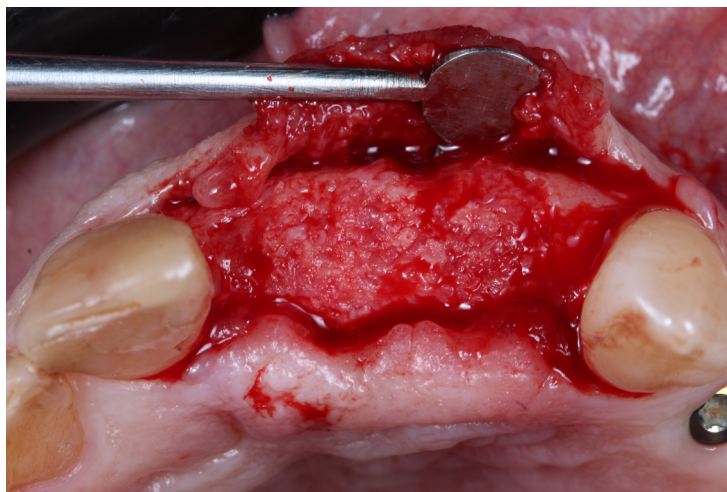




Follow Up  $\approx$  **06 meses**



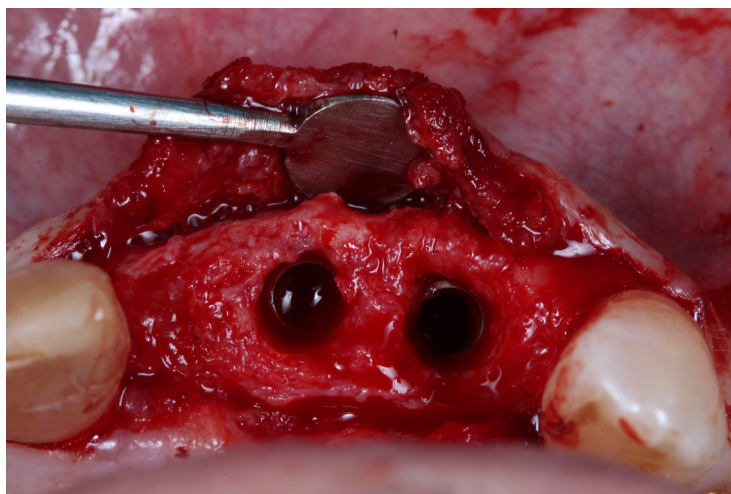

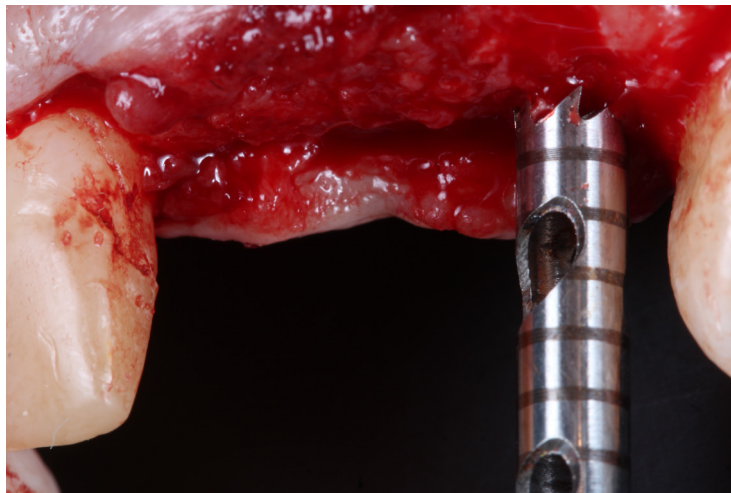
Situação clínica após **06 meses** de cicatrização



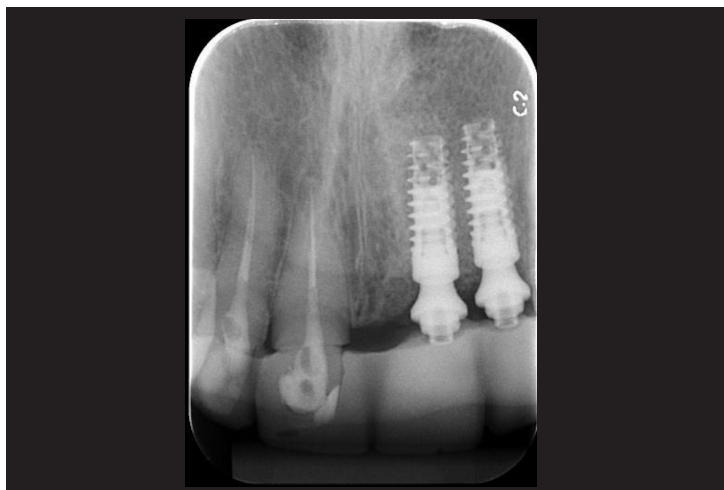**Tecido ósseo neoformado**

Follow Up  $\approx$  **06 meses**

Follow Up  $\approx$  **06 meses**



**Biomorse SWE 4,0 x 11,5 mm [Cod 11027 Lote 062910]**



**Follow Up ≈ 12 meses [29 MAI 2019]**