



CASE 15

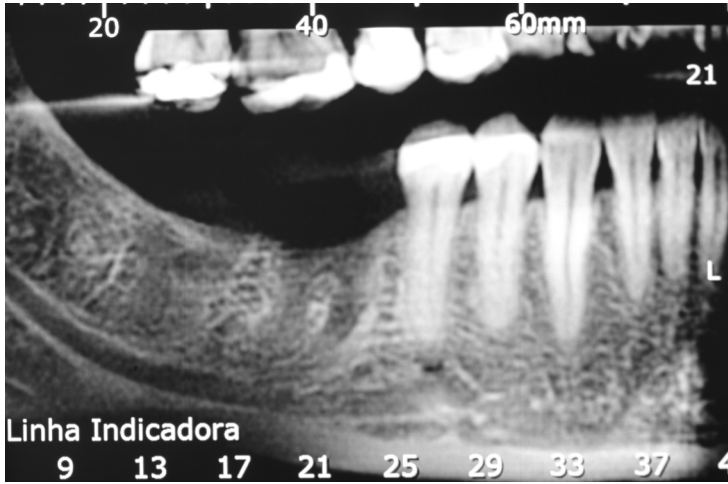Cirurgião: Fábio Shiniti **MIZUTANI**

Diagnóstico: Exodontia com instalação de implantes BioDIRECT SWE 46/47

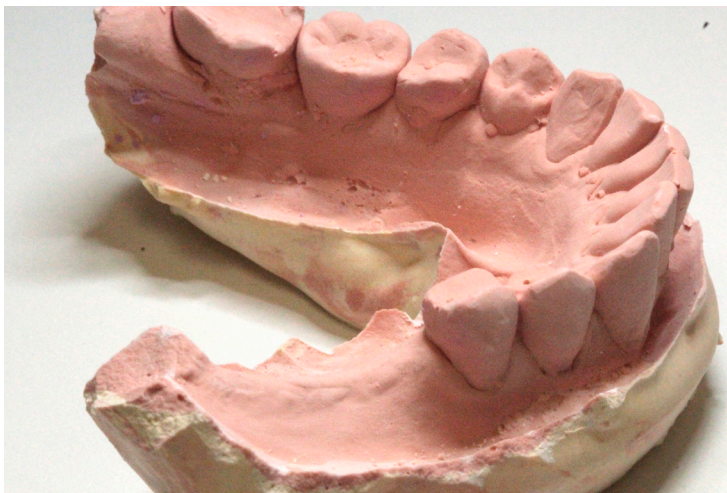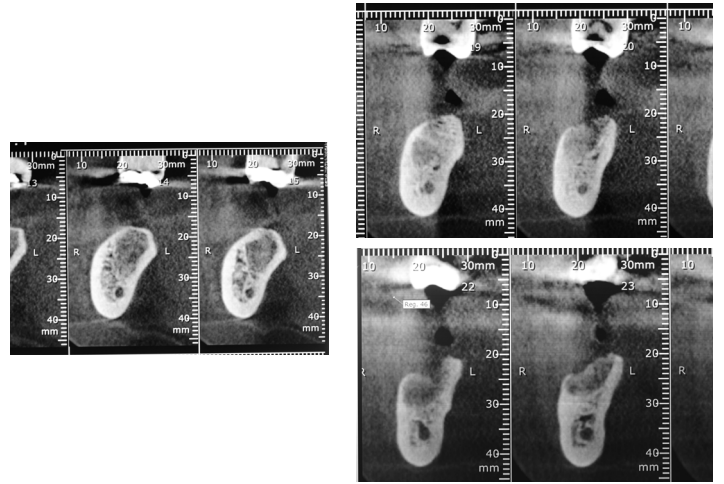
Histórico:

Paciente: M.F.D, 42 anos, sexo feminino,

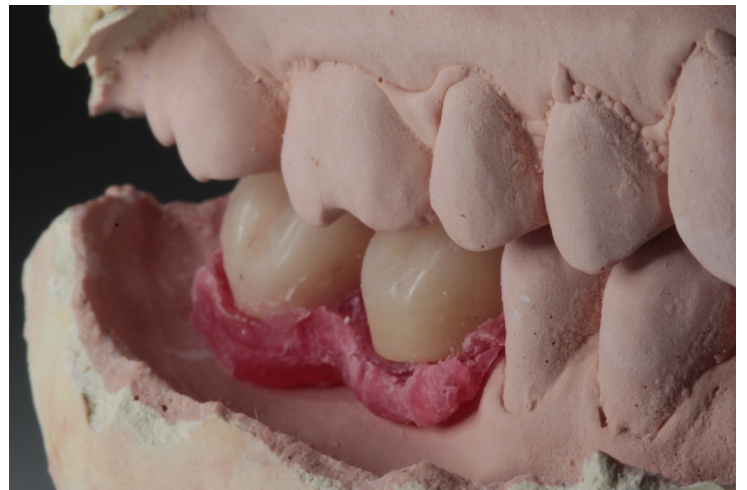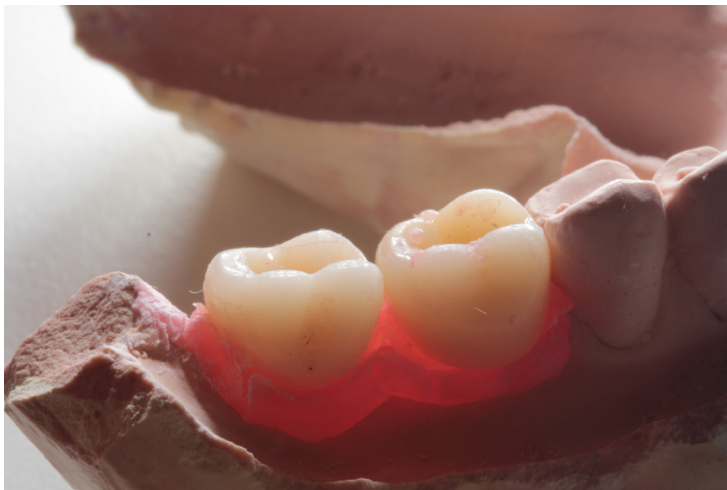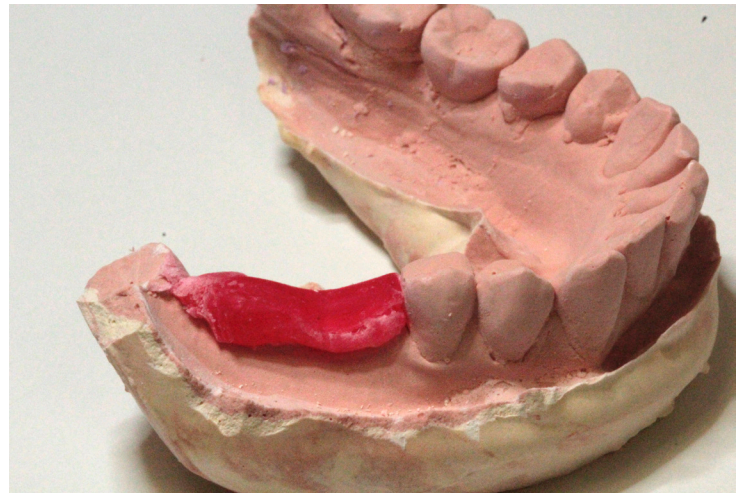
Exodontia do dente trincado **47** [10/11/15]. Exodontia do dente fraturado **46** [11/03/17] preparando para futura instalação de implantes BioDIRECT SWE

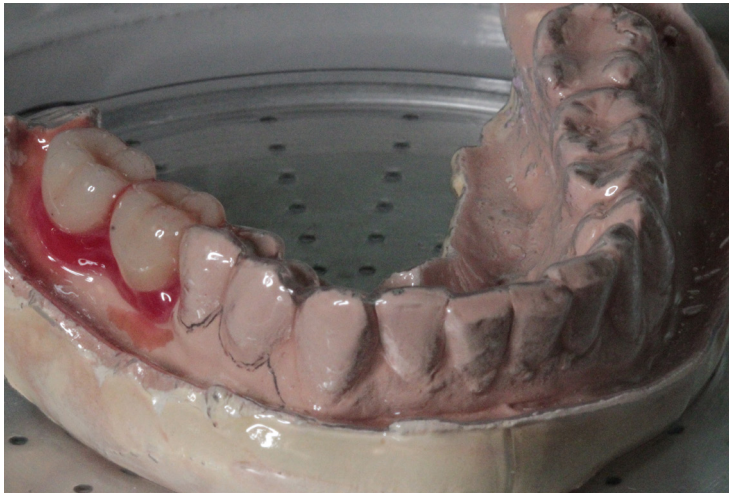

Radiografia Inicial [14 SET 2016]

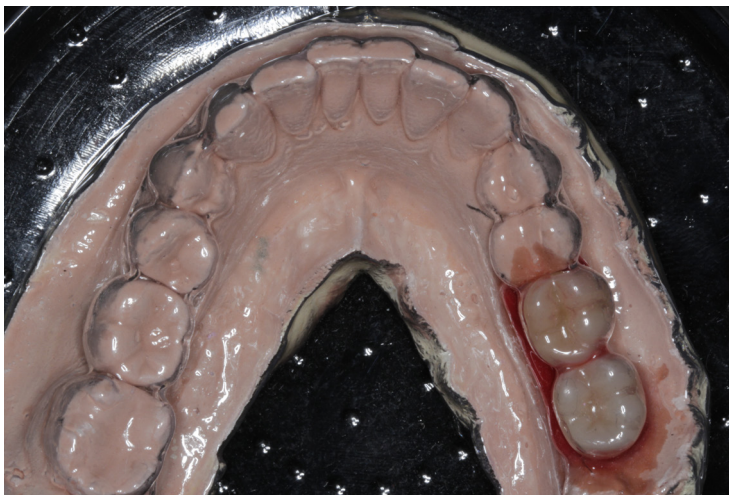
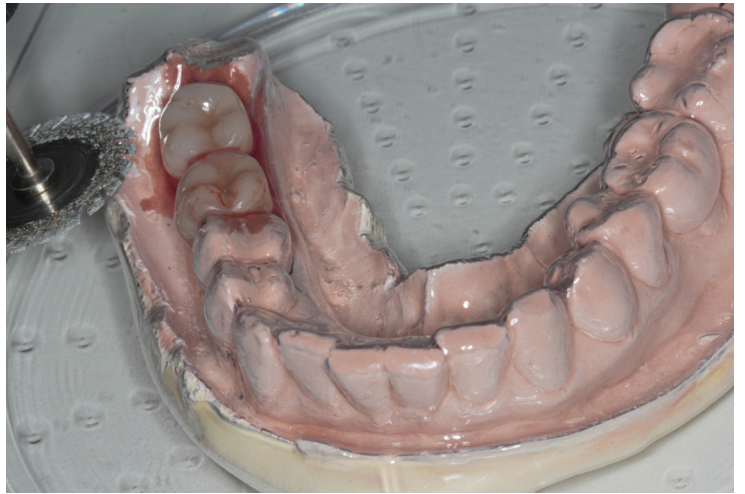


Preparação do Guia Cirúrgico [10 AGO 2017]

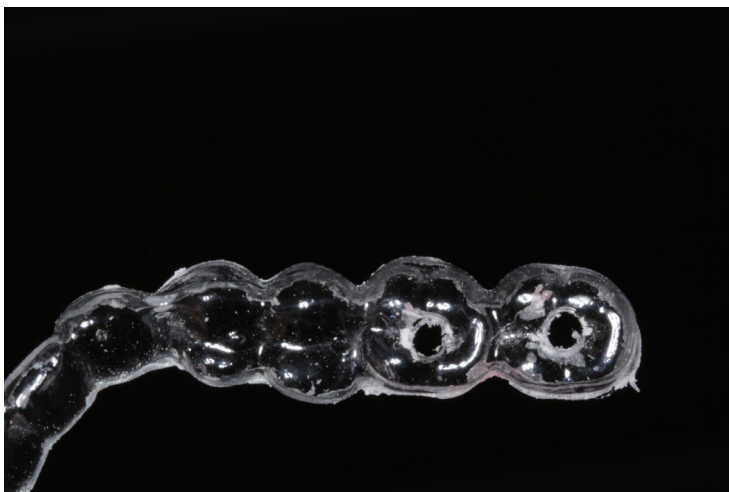
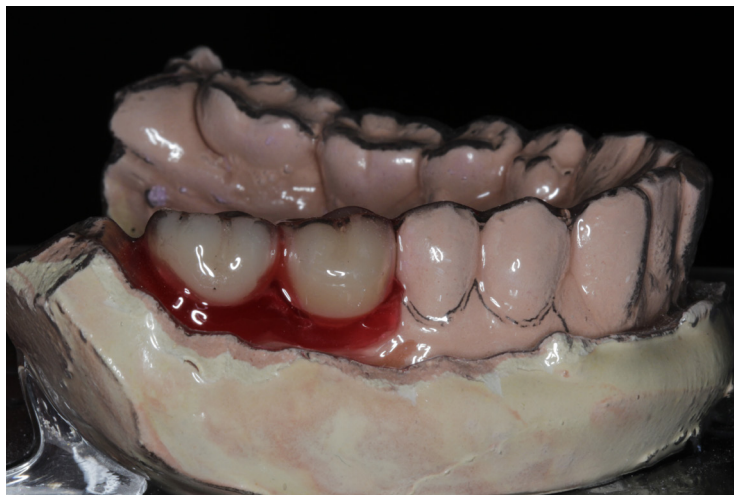


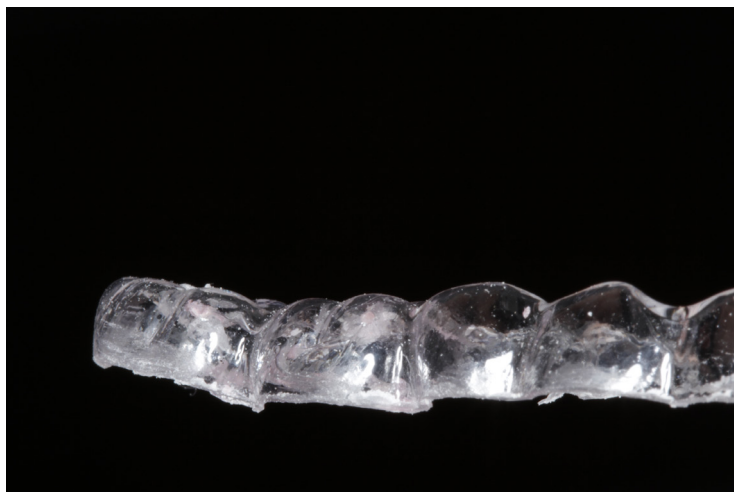Enceramento diagnóstico

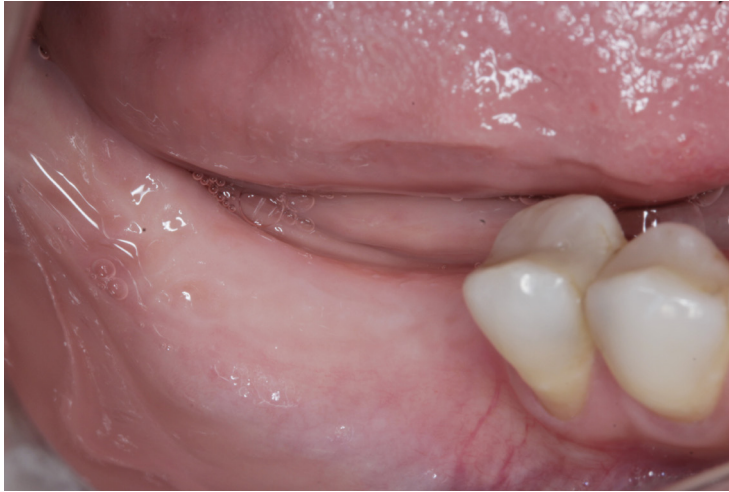

Prensamento de placa de acetato de 1mm

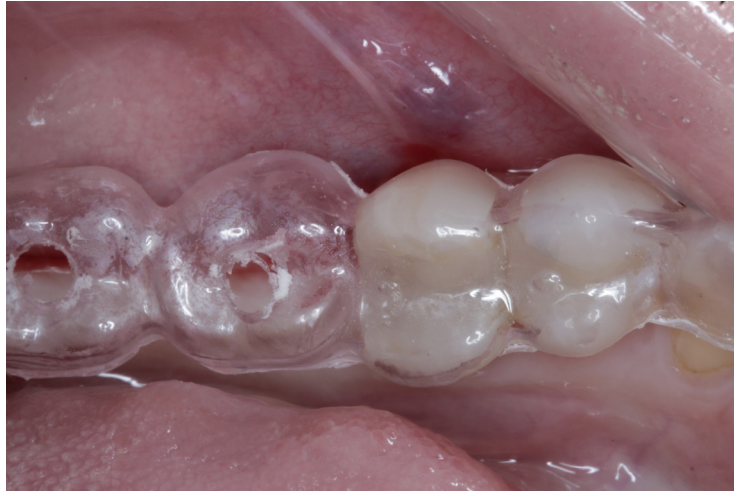

Guia cirúrgico

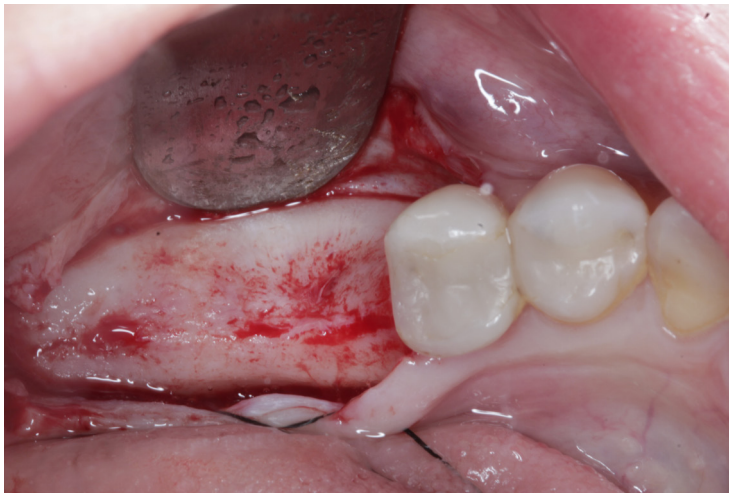




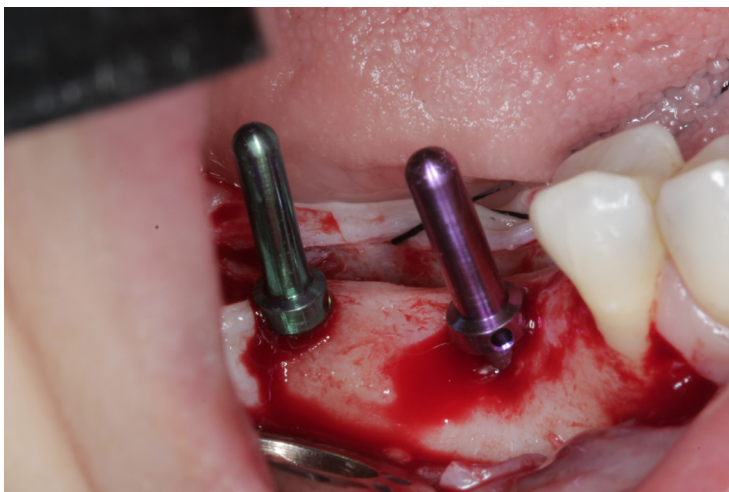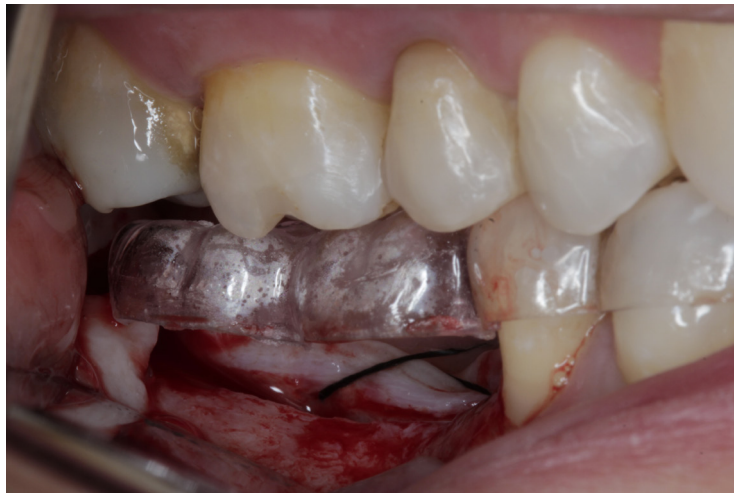Visão Pré Operatório



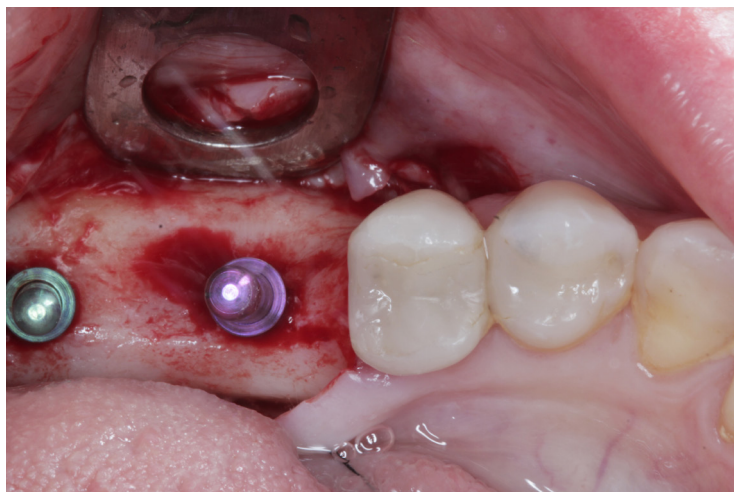
Teste do guia cirúrgico

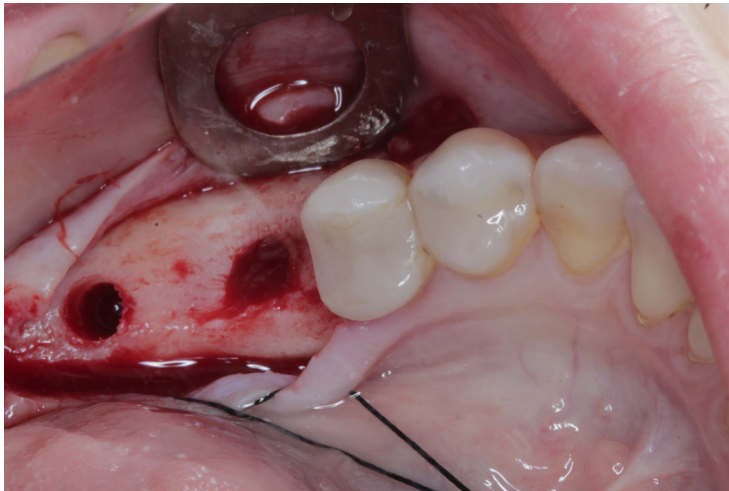

Abertura do retalho total

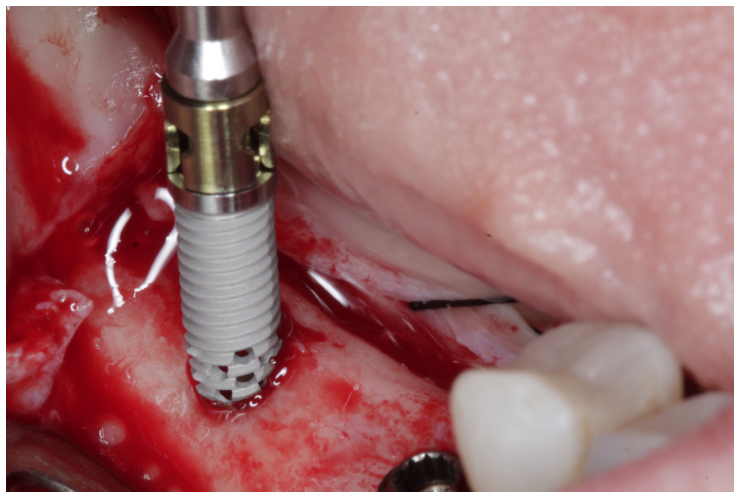
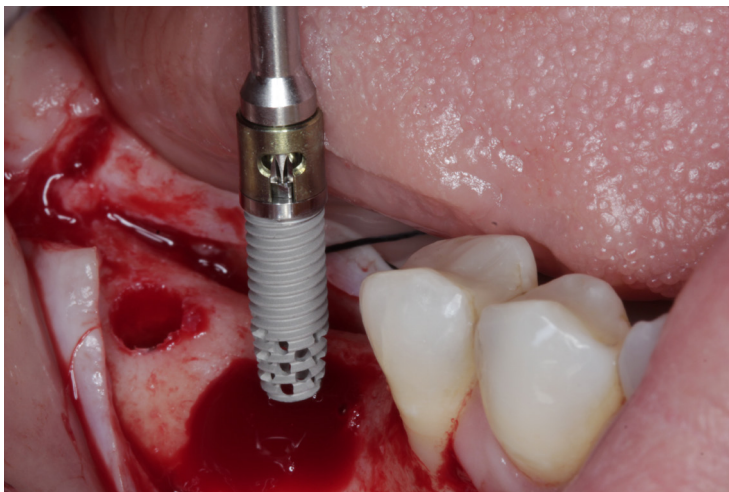
Observação de Paralelismo

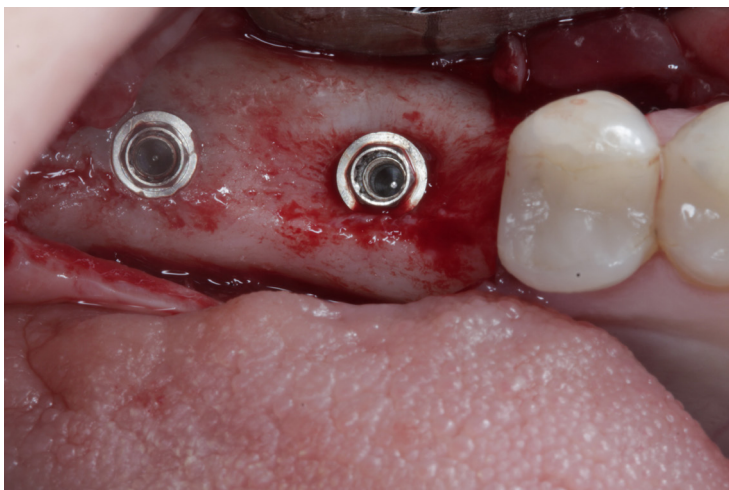




Implante BioDIRECT SWE [Cod 35112 Lote 059663]



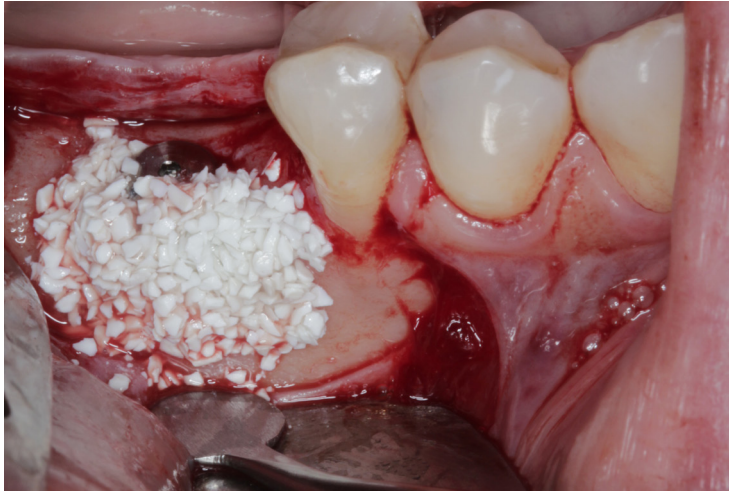Instalação dos Implantes BioDIRECT SWE



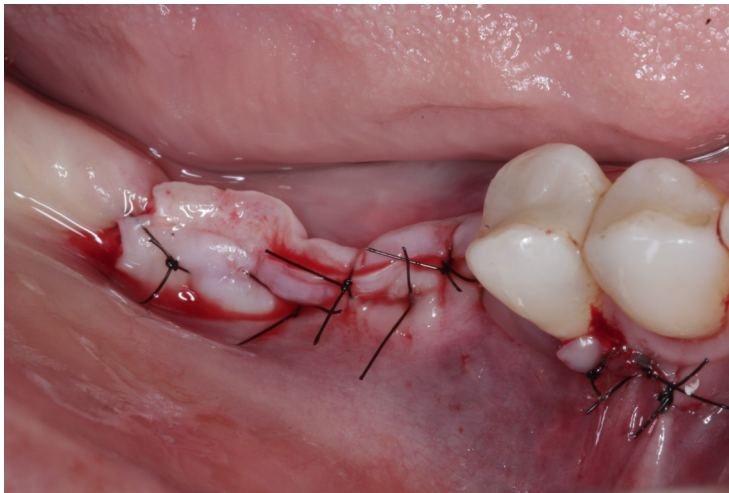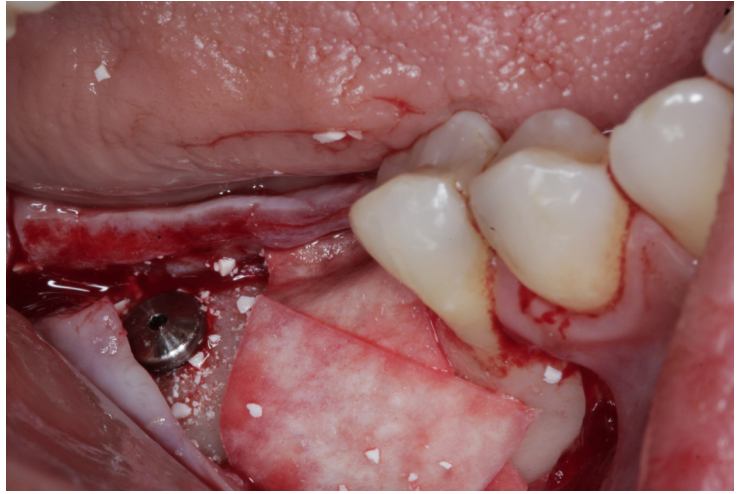
Vista oclusal do implante instalado



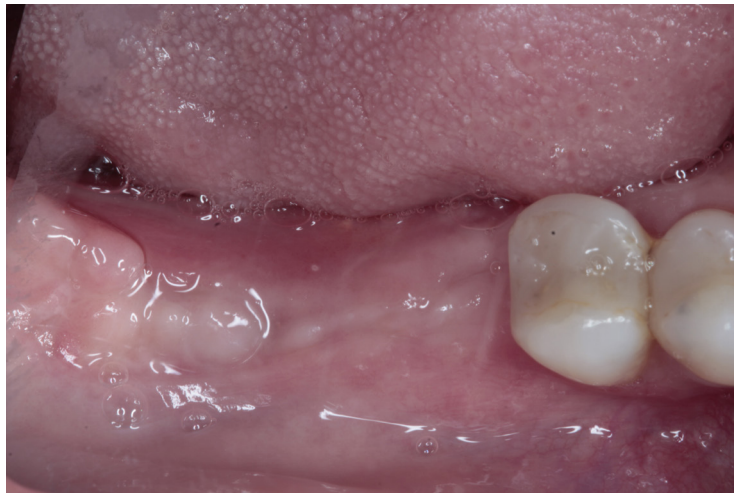Rastreabilidade



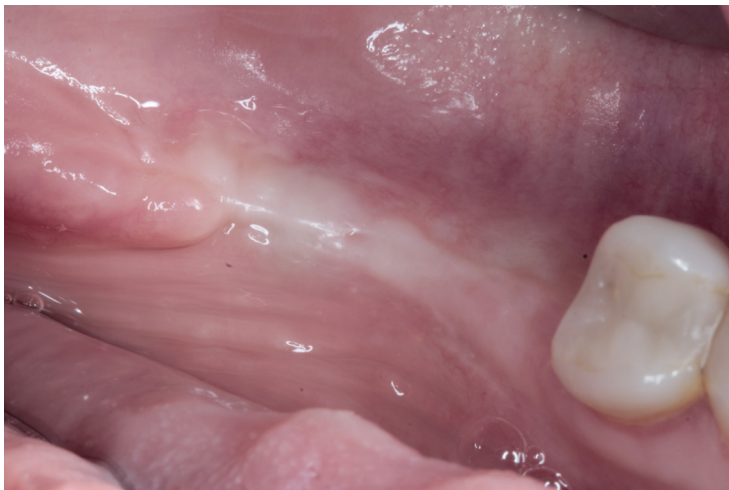Hidroxiapatita [Cod 16031 Lote 059549]



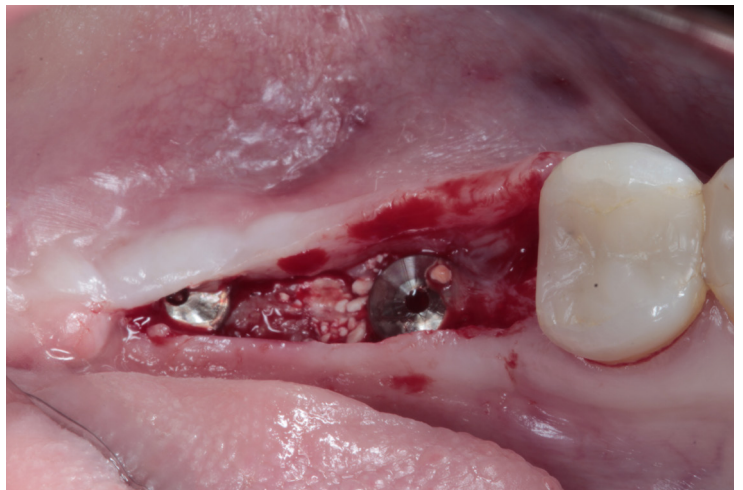Sutura



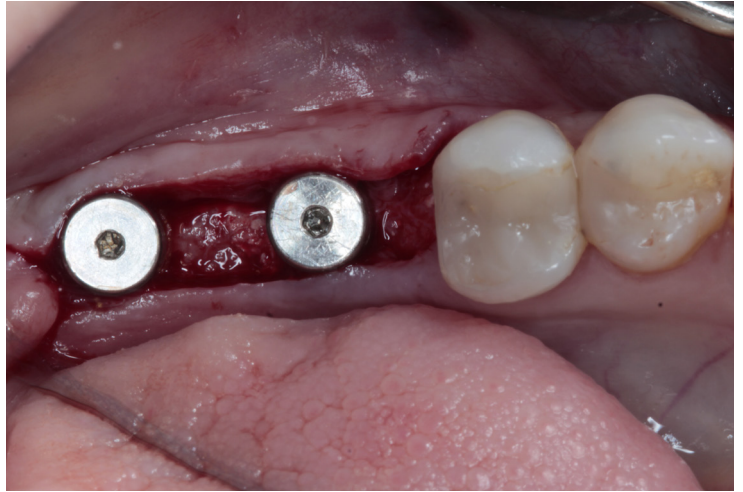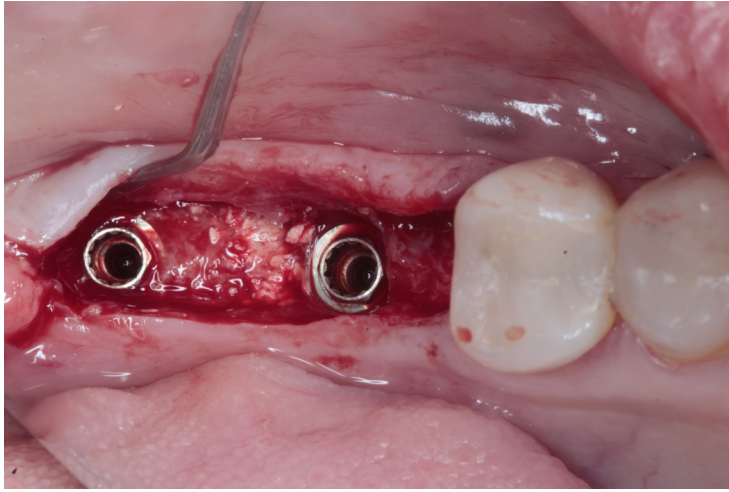
Follow Up 7 dias



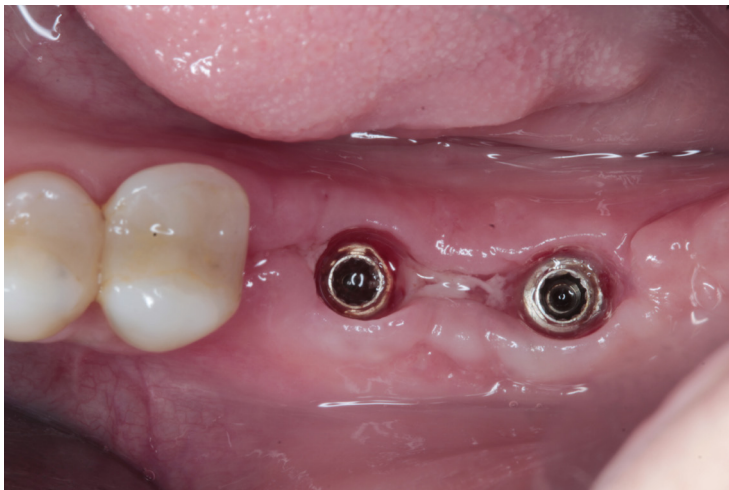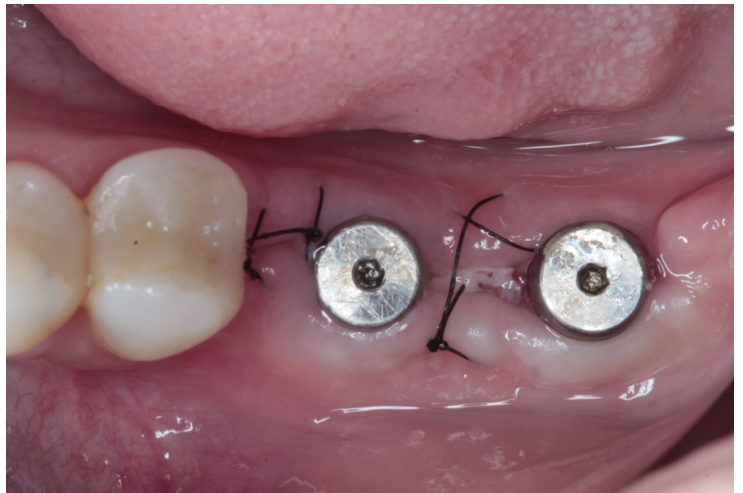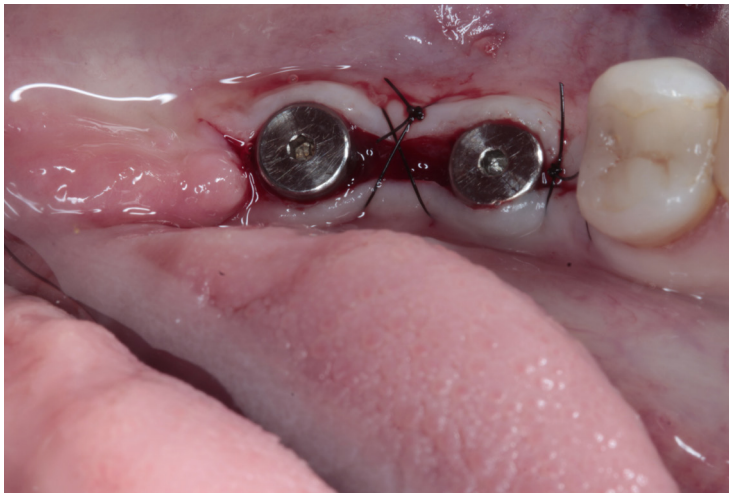
Follow Up 3 meses



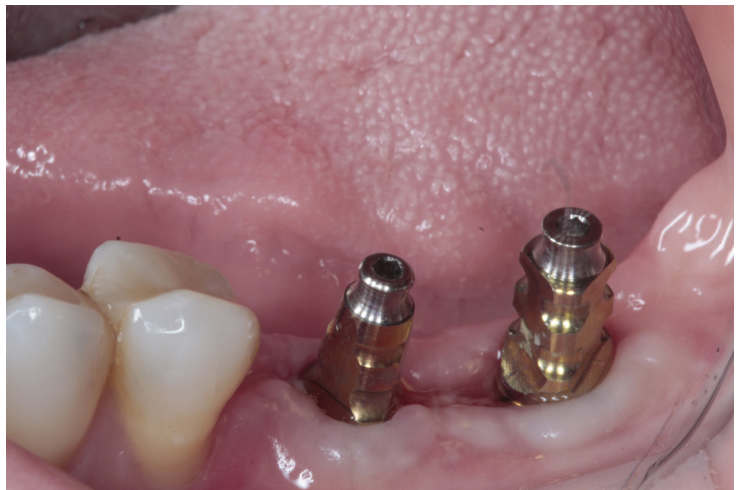Reabertura 3 meses



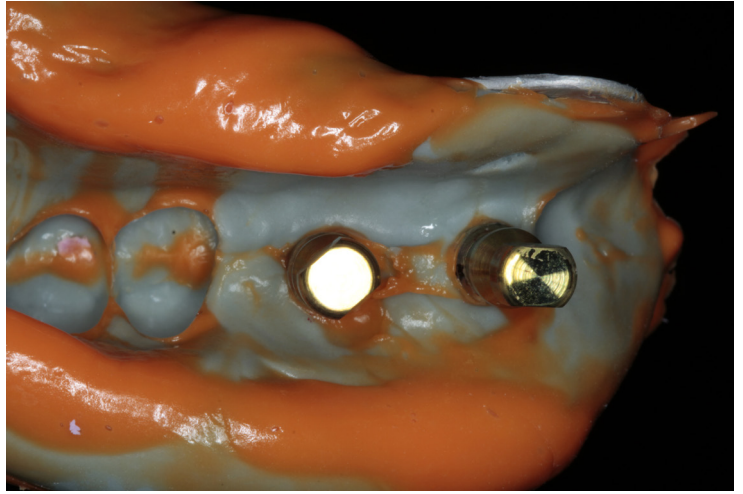
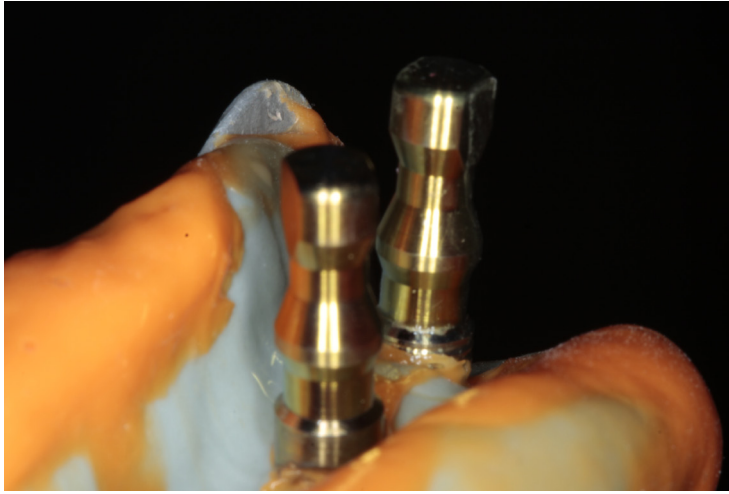Instalação dos cicatrizadores



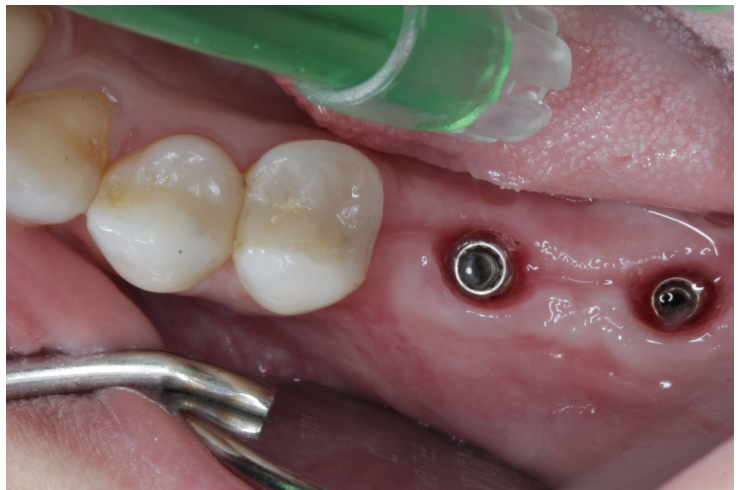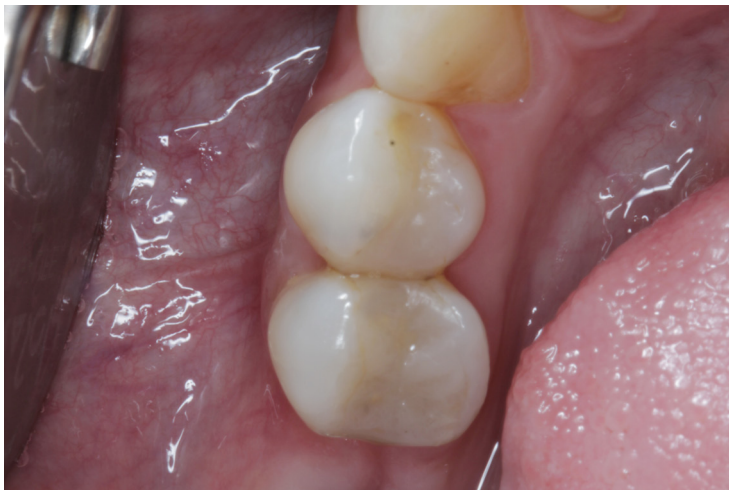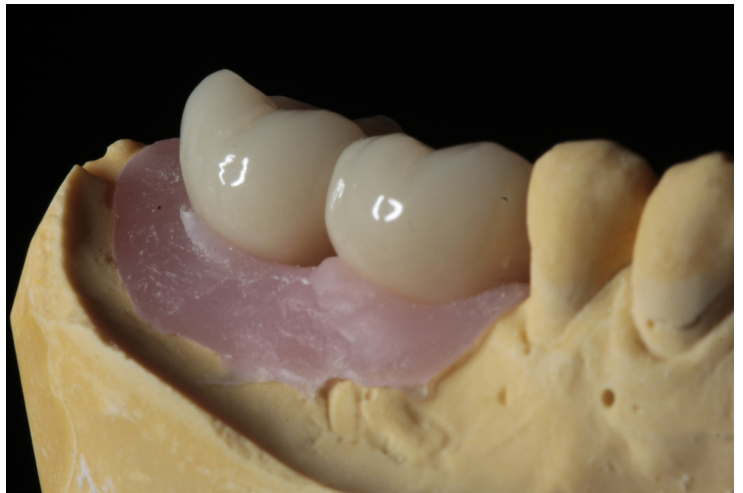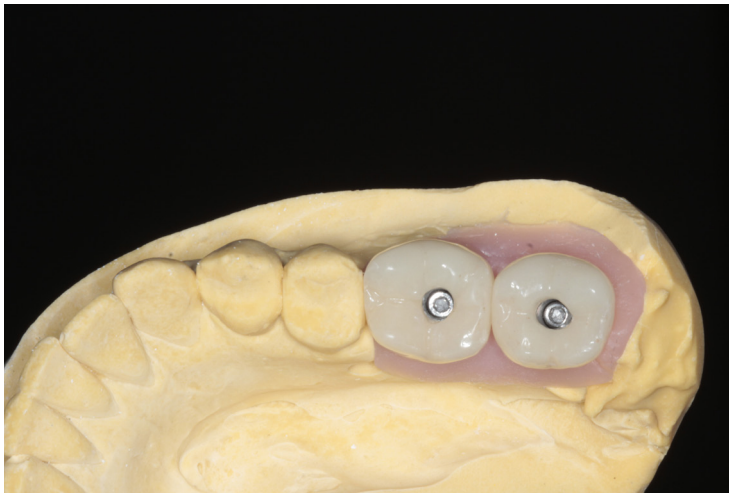
Follow Up 21 dias [Pós instalação cicatrizador]

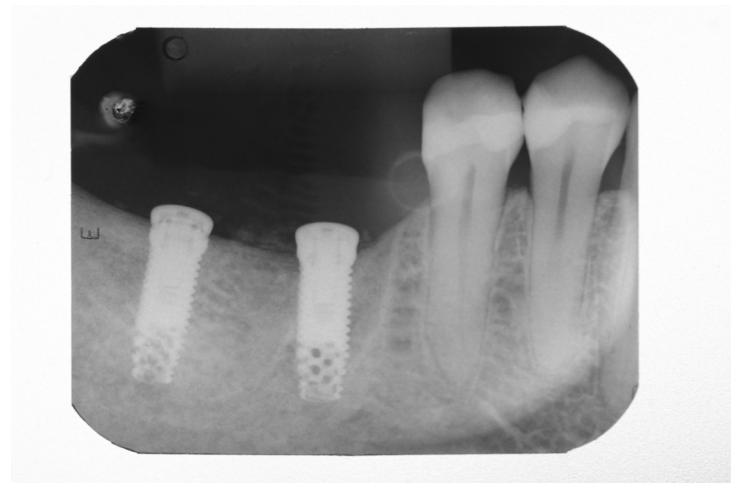
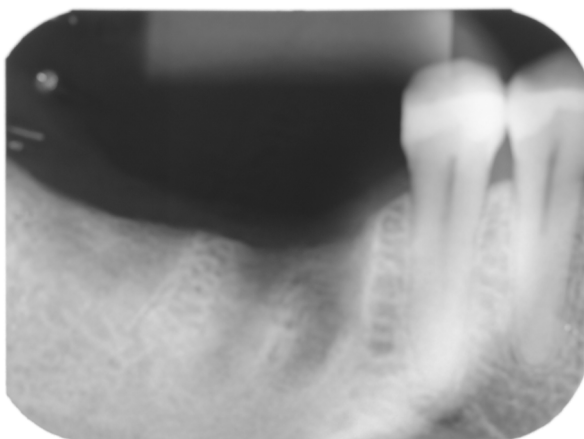
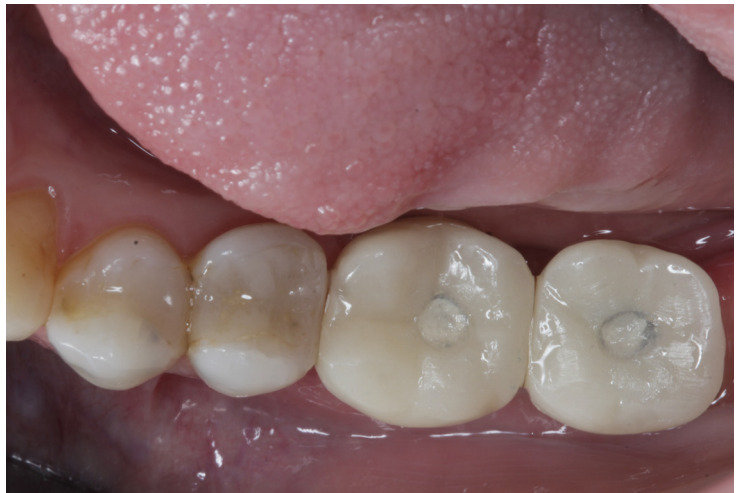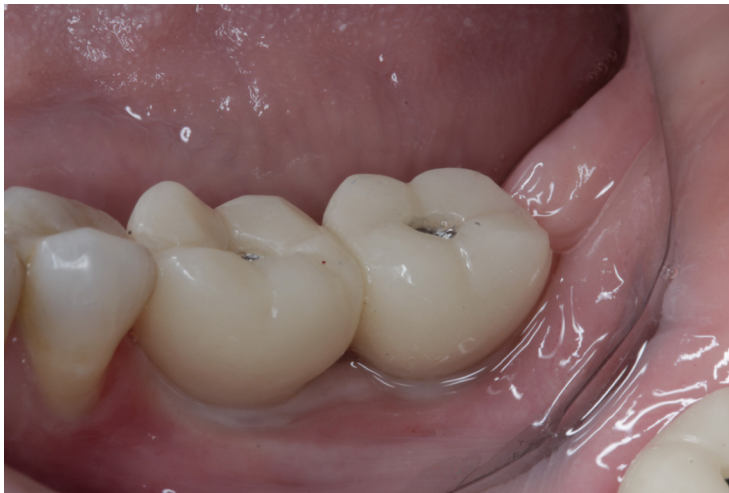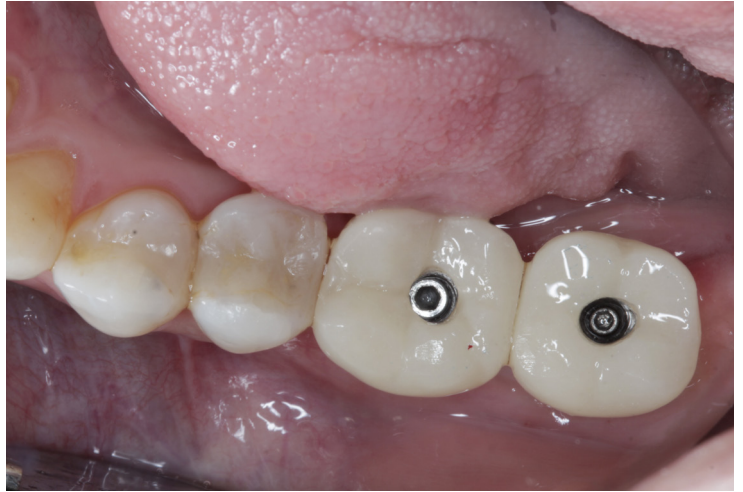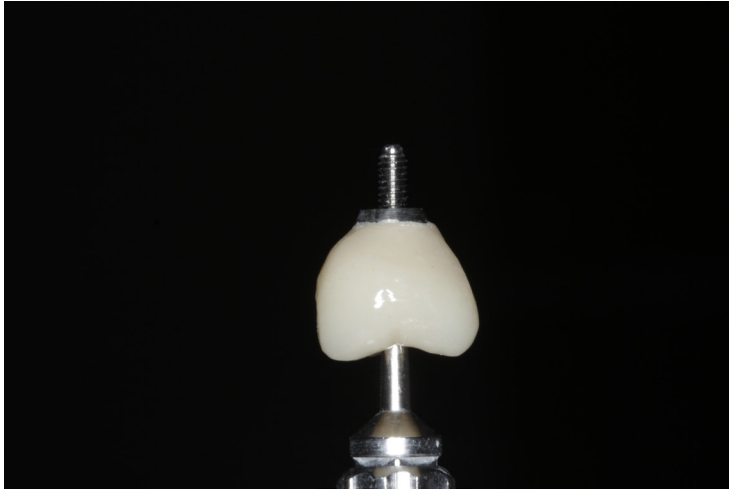


Análogo RP [Cod 08007 Lote 061520]



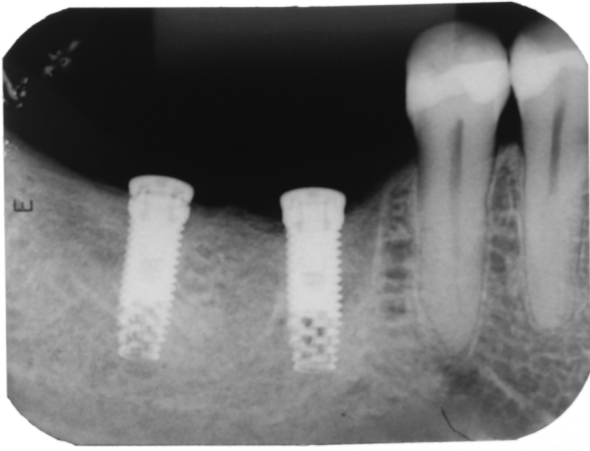
Análogo RP [Cod 09004 Lote 062589]



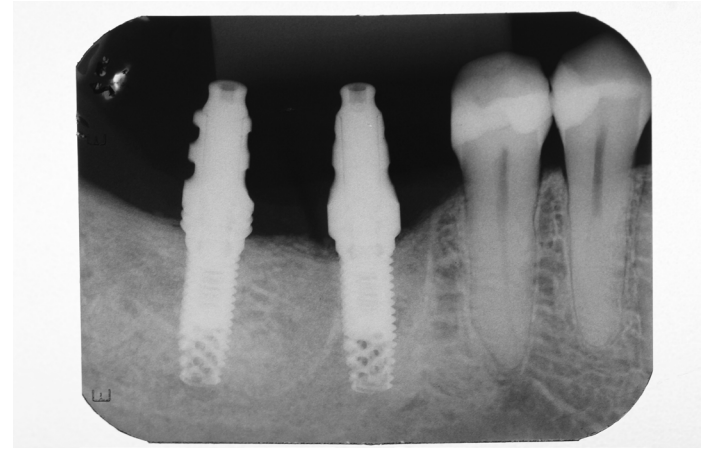


Raio X Pós Extração dentes 46 / 47 [18 NOV 2017]

Follow Up Imediato [18 NOV 2017]



Follow Up ≈ **05 meses** [21 MAI 2018]



Follow Up ≈ **06 meses** [19 JUN 2018]
