



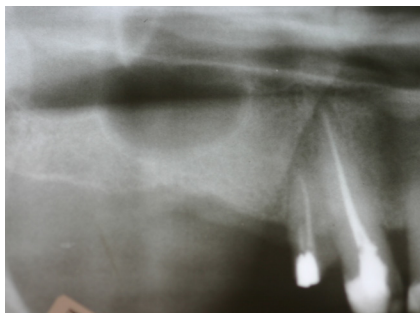
CASE 09

Cirurgiões: José Henrique **VILLAÇA**

Diagnóstico:

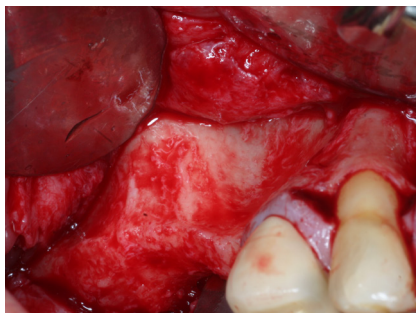
Paciente:

Follow Up ≡



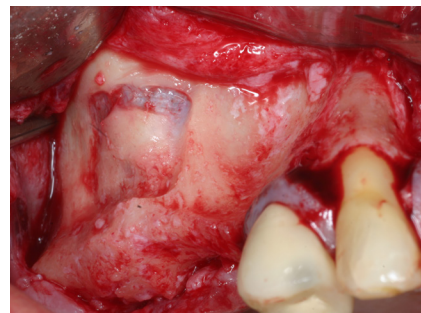
Panorâmica pré-operatória

Panoramic image before sinus augmentation procedure



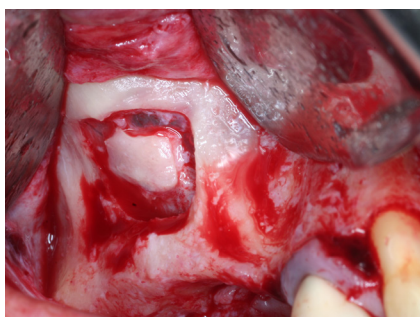
Procedimento cirúrgico de elevação seio maxilar

Surgical procedure of sinus lift



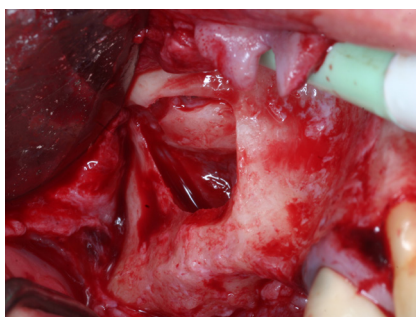Preparação da janela óssea

Preparation of bony window



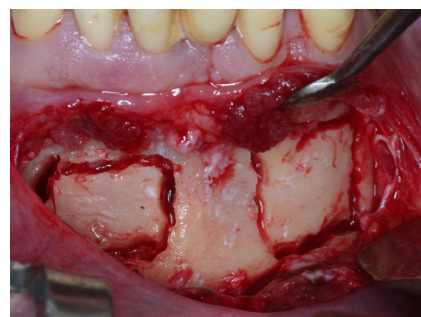
Cavidade do seio maxilar após o desprendimento da membrana sinusal.

Maxillary sinus cavity after membrane detachment



Descolamento completo da membrana sinusal preparando para enxerto ósseo.

Elevator used to detach the sinus membrane, creating the region for the bone graft



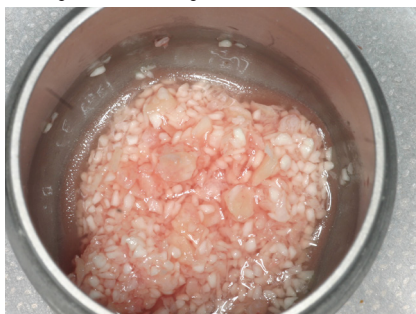Osteotomia na região de mento

Bone graft being harvested from the chin region



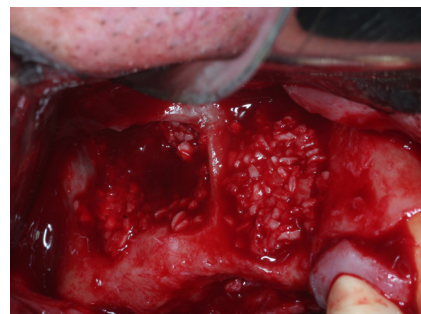
Mix de osso autógeno com osso xenógeno (Bonefill Denso).

Mixture of autogenous bone and Bonefill Dense



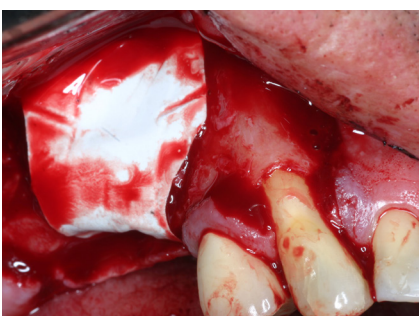Mix de osso autógeno com osso xenógeno (Bonefill Denso) hidratados com soro fisiológico.

Mixture of autogenous bone and Bonefill Dense with sterile saline solution.



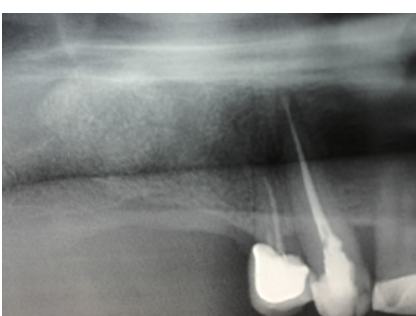
Acomodação do enxerto ósseo no seio maxilar e na região vestibular do rebordo na região do dente 15.

Cavity being filled with the biomaterial (Bonefill Dense + Autogenous)



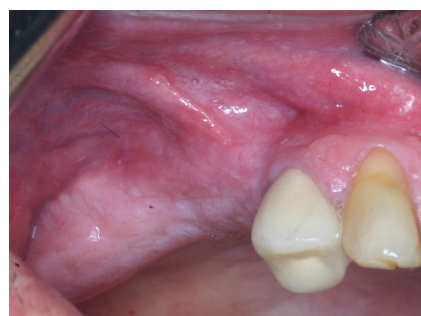
Surgitime PTFE recortada a adaptada

SURGITIME PTFE membrane was placed to cover the lateral window.



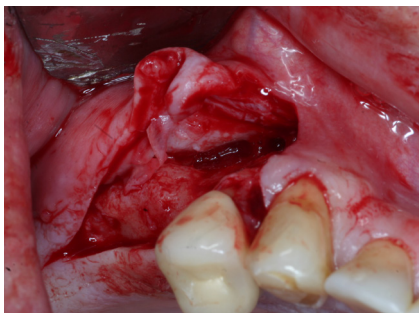
Aspecto radiográfico após 6 meses.

Panoramic x-ray showing the amount of sinus elevation after 6 months.



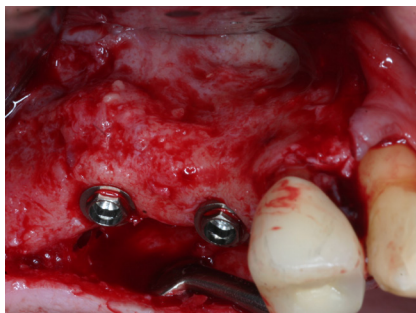Reabertura da área e remoção da membrana.

Re-entry after 6 months, there is already a noticeable increase in volume in region # 15 compared with that before surgery.



Reabertura da área e remoção

Removal of SURGITIME PTFE membrane



Implantes instalados na região de 15 e do 16 evidenciando ótima regeneração óssea.

Implants placed into the grafted sinus after 6 months