



CASE 07

Cirurgiões: Miriam **MICHELIN**

Diagnóstico:

Paciente:

Follow Up ≈

Caso Clínico

Clinical Case

Correção de Insucesso de Enxerto Ósseo em Seio Maxilar

Sinus Augmentation

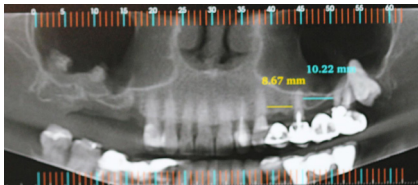
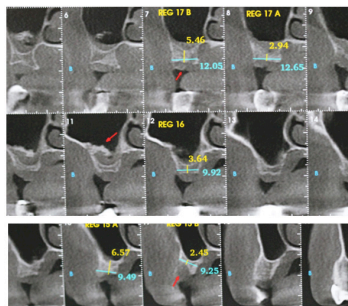


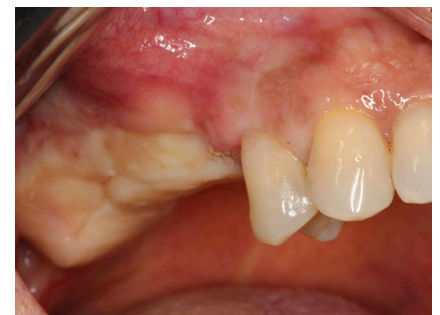Imagem panorâmica inicial obtida do exame tomográfico.

Initial radiographic appearance



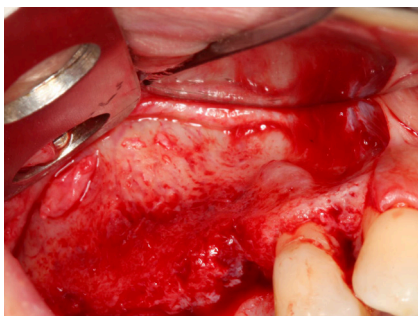
Cortes tomográfico transversais pré-operatórios.

Transaxial computed tomography image



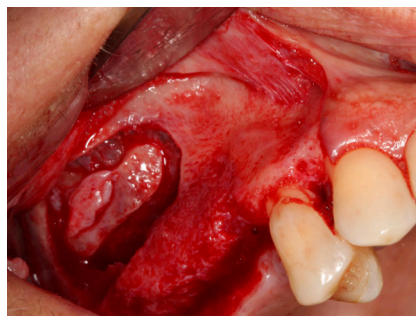
Exame clínico inicial.

Clinical situation pre-operatively



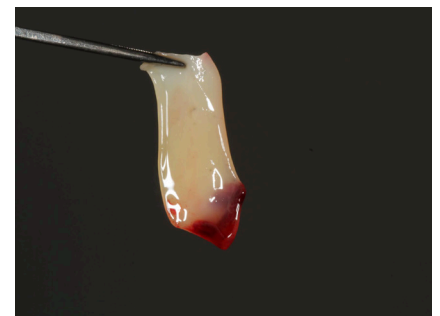
Descolamento de retalho único.

Lateral aspect of buccal bone after flap elevation.



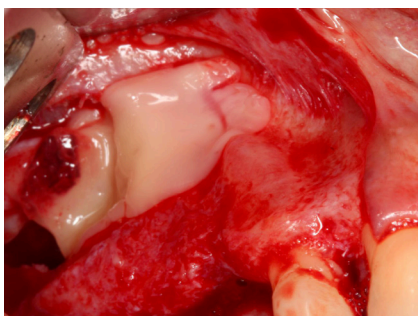
Descolamento da membrana do assoalho do seio maxilar.

Sinus augmentation using the lateral window technique.



Plugs de PRF.

PRF Plugs.



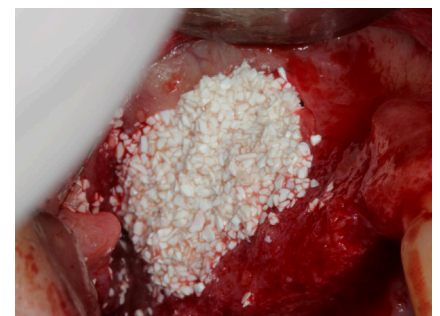Membranas de PRF colocadas dentro da cavidade.

PRF clots were filled inside the sinus cavity.



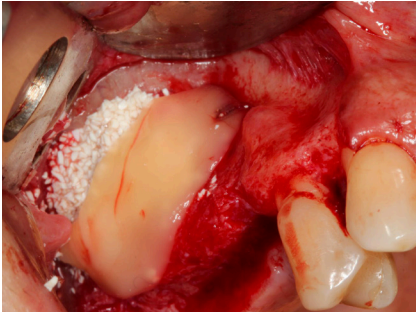
Hidroxiapatita agregada ao PRF como material de preenchimento do seio maxilar.

The mixture of PRF and Bionnovation Hydroxyapatite.



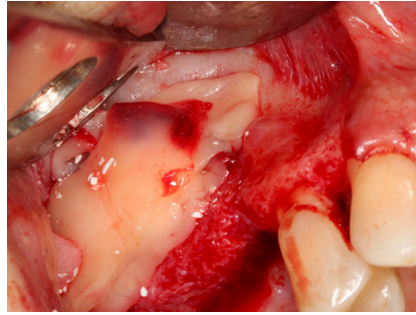
Preenchimento da cavidade sinusal com Hidroxiapatita agregada ao PRF.

Sinus augmentation with a mixture of hydroxyapatite and PRF.



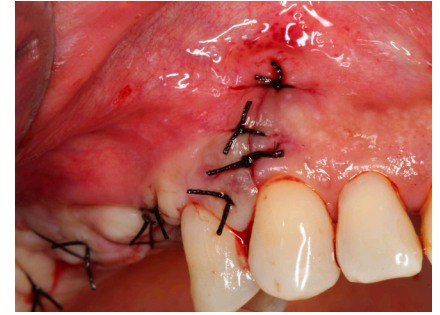
Membrana de PRF recobrimo o material de preenchimento.

PRF membrane was used to cover the bone graft.



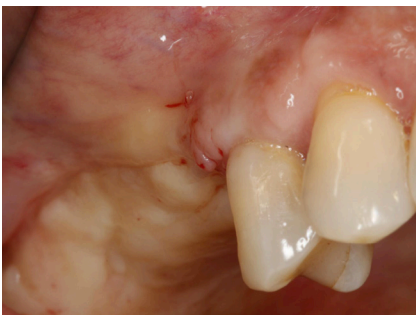Membrana de PRF utilizada para cobrir a janela de osteotomia.

PRF membrane was used to cover the osteotomy window.



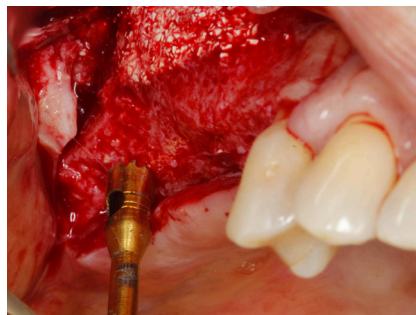
Fechamento e sutura final

Final closure and suturing



Exame clínico após 6 meses

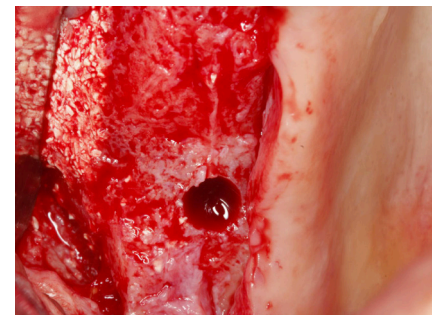Clinical situation 6 months post-operative.



Re-entrada 6 meses

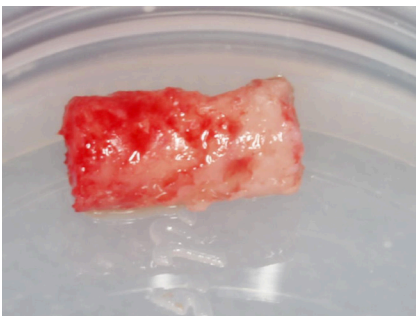
Broca trefina colhendo material para análise histológica do sítio de instalação de implante

*Re-entry after 6 months
Trephine biopsy collection*



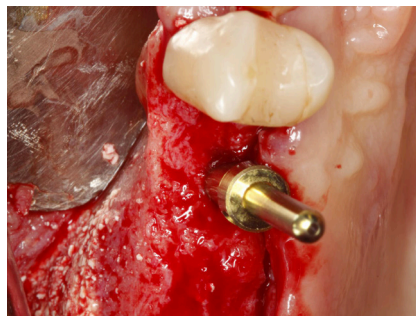Aparência após remoção da amostra para análise histológica

Appearance after removal of trephine biopsies.



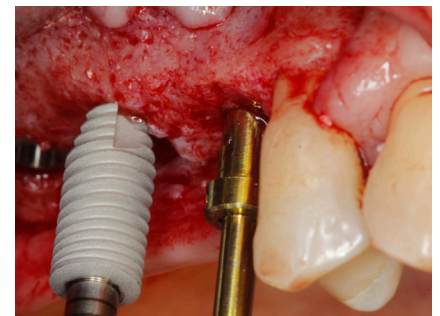
Amostra removida (3 milímetros)

Sample of the bone core biopsies (3 millimeter diameter)



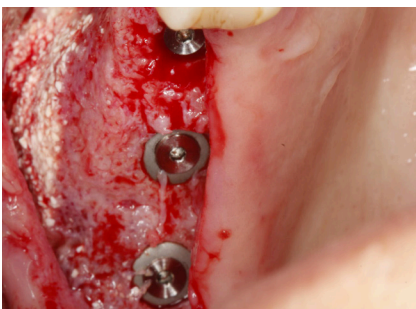Instalação dos implantes Biomorse

Biomorse implant placement into the maxillary sinus graft.



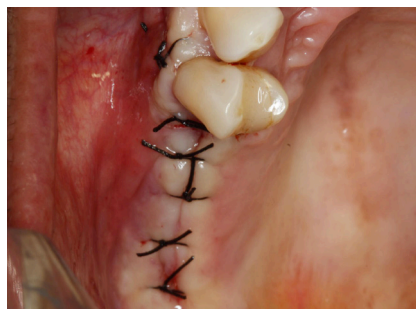Instalação dos implantes Biomorse

Biomorse implant placement into the maxillary sinus graft.



Implantes Biomorse instalados.

Biomorse implants placed.



Estabilização do retalho com suturas.

Final closure and suturing.

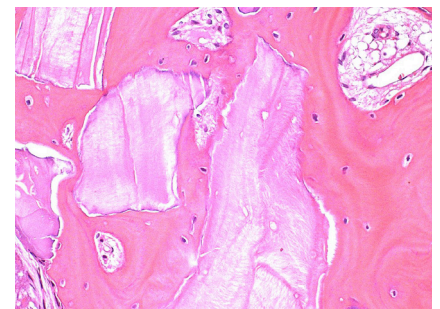


Imagem histológica de tecido ósseo mostrando boa integração de partículas do Bonefill Porous no osso recém-formado.

Histological examination in higher magnification of a sample harvested 6 months after surgery using PRF and Hydroxyapatite shows extremely mature bone

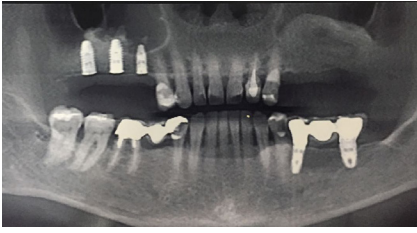


Imagem panorâmica dos implantes instalados

Panoramic radiograph of the dental implants placed in the re-grafted
