



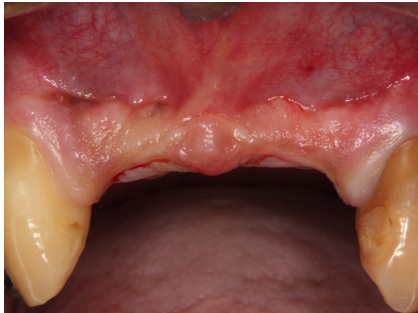CASE 04

Cirurgiões: Danilo **MAEDA**

Diagnóstico:

Paciente:

Follow Up ≡



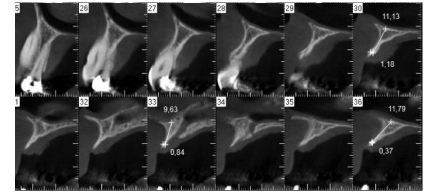
Condição inicial demonstrando a falta de volume na região entre caninos superiores

Clinical situation pre-operatively

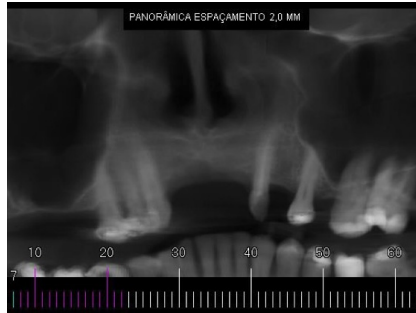

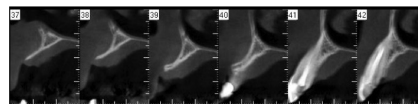
Imagem panorâmica inicial obtida do exame tomográfico

Panoramic computed tomography images



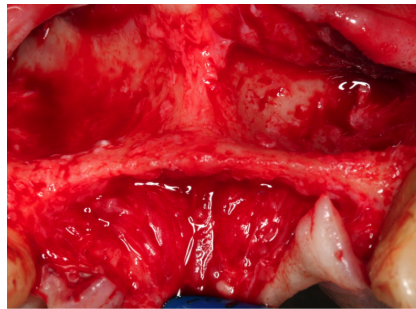
Cortes transaxiais, demonstrando a impossibilidade de inserção de implantes

Transaxial computed tomography images showing insufficient bone for implant placement

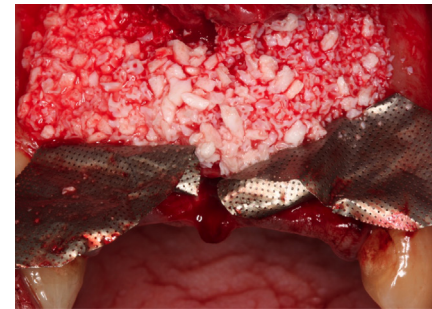


Cortes trans-axiais, demonstrando a impossibilidade de inserção de implantes

Transaxial computed tomography images showing insufficient bone for implant placement



Retalho elevado demonstrando a concavidade óssea e ausência de espessura óssea



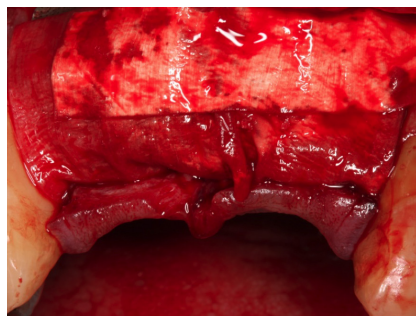
Preenchimento do defeito com hidroxiapatita e estabilizado com malhas de titânio

The defect is filled with Hydroxyapatite which is stabilized with Titanium Mesh



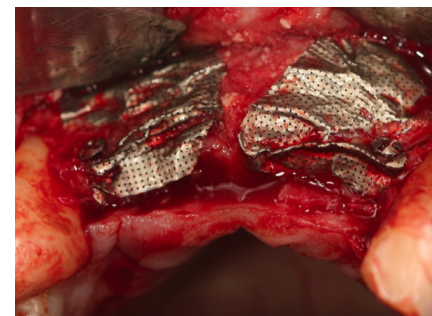Cod. 16565 Surgitime Titânio

Cod 16565 Surgitime Titanium



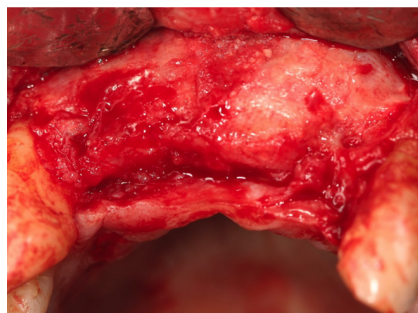
Membrana colágena aplicada sobre as malhas de titânio

Collagen membrane placed over the Titanium Mesh



Reabertura após 6 meses antes da remoção da membrana de titânio

Reopening 6 months later before removing the titanium membrane



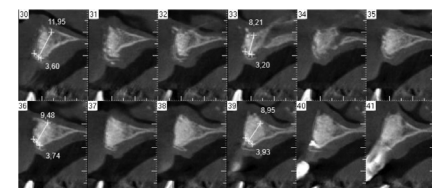
Reconstrução óssea obtida após 6 meses (Observar o grande ganho ósseo)

Clinical aspect of the augmented bone after 6 months

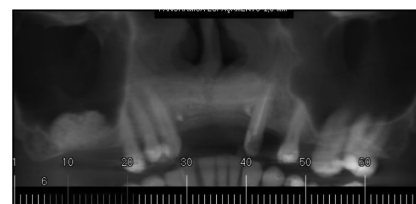

Imagem panorâmica após 6 meses obtida do exame tomográfico

Panoramic computed tomography images: 6 months



Cortes trans-axiais do resultado obtido após 6 meses

Transaxial computed tomography images: 6 months