



## CASE 02

---

Cirurgiões: Danilo **MAEDA**

---

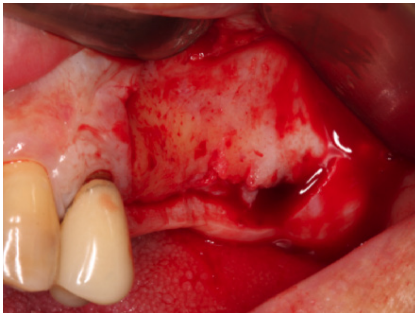
**Diagnóstico:**

---

**Paciente:**

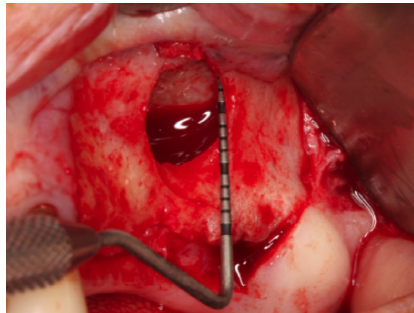
---

Follow Up ≈



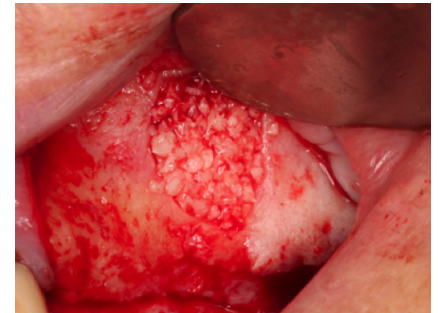**Situação clínica pré-operatória**

*Clinical situation pre-operatively*



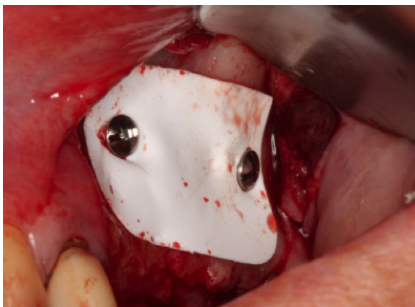**Vista clínica da área do seio maxilar**

*Clinical view of the Sinus lift area.*



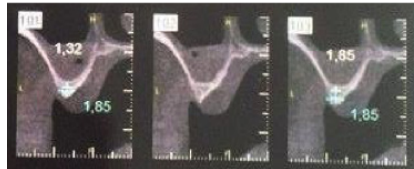
**Bonefill Porous preenchendo completamente a janela lateral alinhada com a parede do osso vestibular.**

*Bonefill Porous completely fills the lateral window aligned with the buccal bone wall*



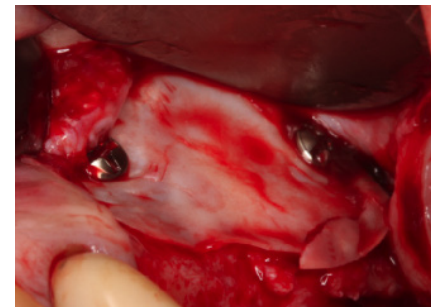
**A janela lateral é coberta com membrana de PTFE (Surgitime PTFE)**

*The lateral window is covered with a Surgitime PTFE barrier*



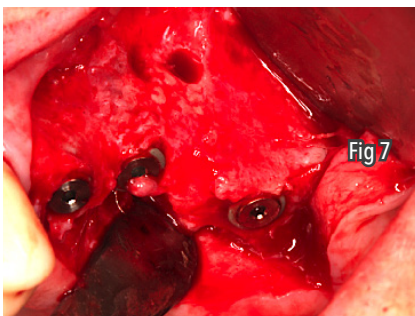
**Cortes transaxiais inicial**

*Initial Transaxial computed tomography images*



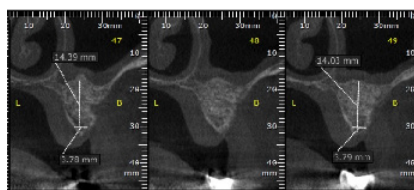
**Remoção da membrana de PTFE (Surgitime PTFE) após 6 meses**

*After 6 months the PTFE barrier was removed*



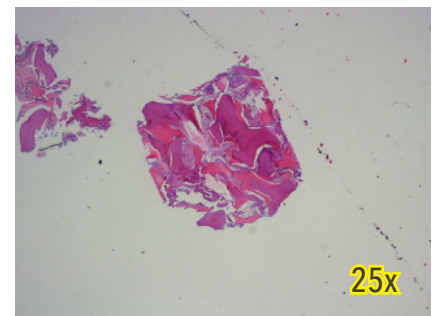
**Resultado após remoção da membrana de PTFE (Surgitime PTFE)**

*Immediate result following removal of the PTFE barrier*



**Cortes transaxiais: 6 meses**

*Transaxial computed tomography images: 6 months*



**Histológico: ilustra um aumento significativo na neoformação óssea**

*Histological: Illustrates a significant increase in bone neoformation*

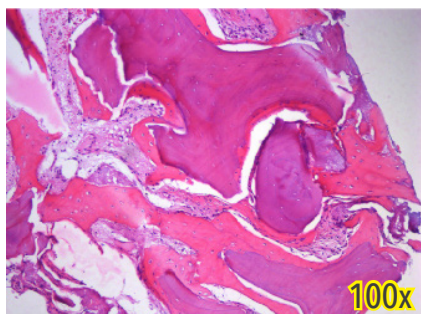


Imagem histológica de tecido ósseo mostrando boa integração de partículas do Bonefill Porous no osso recém-formado.

*Histological image of the regenerated bone tissue showing good integration of Bonefill Porous particles into newly generated bone*

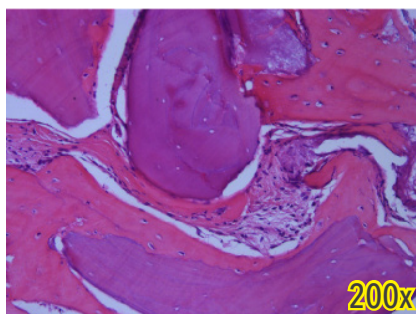
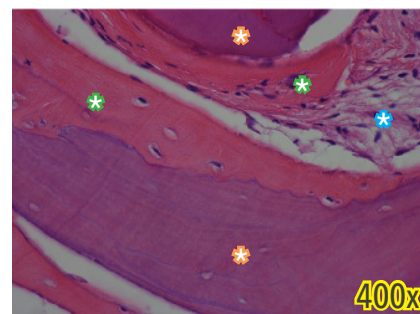


Imagem histológica de tecido ósseo mostrando boa integração de partículas do Bonefill Porous no osso recém-formado.

*Histological image of the regenerated bone tissue showing good integration of Bonefill Porous particles into newly generated bone*



- ✿ Partícula de Bonefill Porous
- ✿ Osso neoformado em contato com o Bonefill Porous
- ✿ Tecido conjuntivo não mineralizado

- ✿ Bonefill Porous granules
- ✿ Newly formed bone in contact with Bonefill Porous
- ✿ Non-mineralized connective tissue